

## Postoperative Complications Following Free Gingival Graft: a Case Report

### Complicações Pós-Operatórias Após Enxerto Gengival Livre: Relato de Caso

Valma da Costa Vieira Schrederhof<sup>a</sup>; Alcione de Fátima Zanatta Filther<sup>a</sup>; Ana Paula Tulio Manfron<sup>a</sup>; Gabriela Fracasso Moraes<sup>\*a</sup>; Humberto Osvaldo Schwartz-Filho<sup>b</sup>

<sup>a</sup>Faculdade Herrero, Post-graduate Program in Dentistry. PR, Brazil

<sup>b</sup>Universidade Federal do Paraná, Post-graduate Program in Dentistry. PR, Brazil.

\*E-mail: E-mail: [gabymoraes0712@gmail.com](mailto:gabymoraes0712@gmail.com)

---

#### Abstract

Among the available techniques for gingival recession treatment, the main surgical technique for gain of keratinized tissue is the free gingival graft. This procedure is also indicated for vestibule extension and frenulum removal. The technique consists of the epithelial and connective tissues removal from a donor site and its repositioning on to a recipient site, being an effective primary stability mandatory for the healing process. The aim of this study was to describe a case report of a 35-year-old male, who reported a postoperative complication in donor area, after a free gingival graft which occurred 07 days later. This situation occurred after patient reported having rinsed his mouth with hot water during shower. Due to that, a 1mm thick acetate tray was readymade for the donor site comfort and protection. Among the demands presented in this case, free gingival graft was the primary surgical choice to increase keratinized tissue. Despite the patient's morbidity, due to the two surgical sites, the use of the acetate tray showed great reduction in patient's discomfort and trauma. This approach proved to be successful since the patient described increase in self-esteem and oral hygiene facilitation which in combination contributed to satisfactory final results.

**Keywords:** Periodontics. Gingival Recession. Postoperative Complications.

#### Resumo

*Entre as técnicas disponíveis para o tratamento da recessão gengival, a principal técnica cirúrgica para ganho de tecido queratinizado é o enxerto gengival livre. Este procedimento também é indicado para extensão do vestibulo e remoção do frênulo. A técnica consiste na remoção de tecidos epiteliais e conectivos de um local doador e seu reposicionamento no local receptor, sendo necessária uma estabilidade primária eficaz para o processo de cicatrização. O objetivo deste estudo foi descrever um relato de caso de um homem de 35 anos, que relatou uma complicação pós-operatória na área doadora, 07 dias após a realização de um enxerto gengival livre. Essa situação ocorreu depois que o paciente relatou ter enxaguado a boca com água quente durante o banho. Devido a isso, uma placa de acetato de 1 mm de espessura foi preparada para conforto e proteção do local doador. Entre as demandas apresentadas neste caso, o enxerto gengival livre foi a principal opção cirúrgica para aumentar o tecido queratinizado. Apesar da morbidade do paciente, devido aos dois locais cirúrgicos, o uso da placa de acetato demonstrou grande redução no desconforto e trauma do paciente. Essa abordagem mostrou-se bem-sucedida, uma vez que o paciente descreveu aumento da autoestima e facilitação da higiene bucal, o que em conjunto contribuiu para resultados finais satisfatórios.*

**Palavras-chave:** Periodontia. Recessão Gengival. Complicações Pós-Operatórias

---

#### 1 Introduction

Gingival recession should be considered a multifactorial condition. The most frequent consequences of gingival recessions are root sensibility, food impaction, predisposition to root cavities, pain during tooth brushing or chewing, difficulty controlling oral hygiene and also aesthetic related issues<sup>1-3</sup>

Among the available techniques for gingival recession treatment, the main surgical technique for gain of keratinized tissue is the free gingival graft<sup>3,4</sup>. This procedure is also indicated for vestibule extension and frenulum removal. The technique consists of the epithelial and connective tissues removal from a donor site and its repositioning on to a recipient site, being an effective primary stability mandatory for the healing process<sup>1,3</sup>.

Most documented complications are associated with the donor site. Harvesting of a free soft tissue graft can result in necrosis of graft and palatal tissue, excessive bleeding, prolonged pain/discomfort or infection at the donor and/or recipient sites, and graft shrinkage<sup>5-7</sup>. Based on the importance of developing and maintaining the architecture, esthetics and the periodontal tissues function and considering the importance of documenting any complications associated with donor site, the aim of this study was to describe a case report of a 35-year-old male, who reported a postoperative complication in donor area, after a free gingival graft which occurred 07 days later.

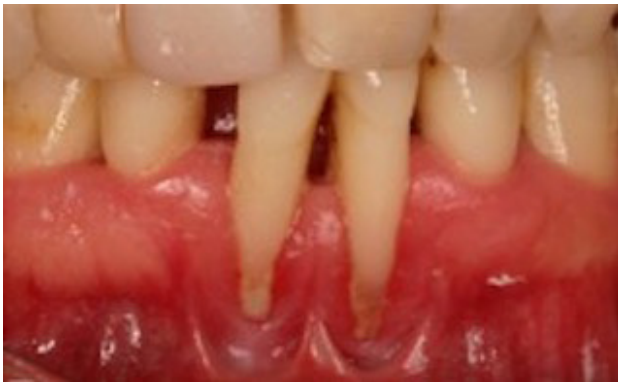#### 2 Case Report

A male, 35-year-old leukoderma patient was referred to clinical service dissatisfied with the aesthetics of his anterior

inferior teeth. Clinical and periodontal evaluation were performed. On the upper jaw probing depths (PD) were between 3-5mm, with little bleeding on probing (BP) and clinical attachment level (CAL) 3-5 mm. On the lower jaw, the same PD and CAL were found but with 90% of bleeding on probing. The O'Leary plaque index was 78%, visible oral hygiene, great amount of calculus and lower bridles positioning on the anterior-low area. Diagnosis was set on Localized Chronic Periodontitis Stage 3 Grade C. Class III Miller recessions were verified on teeth 23, 24 and 25, these teeth also showing mobility. On this area, anomalous position of the bridles and absence of keratinized gingiva were diagnosed.

Basic periodontal treatment was performed with full mouth supragingival scaling, followed by weekly sessions of subgingival scaling and root planning. After 30 days, reevaluation was performed, which clinical improvement of clinical parameters (Figure 1). A free gingival graft was planned and performed to treat the gingival recession and the anomalous bridle position on the lower-anterior area and to increase the amount of keratinized tissue.

**Figure 1** - After 30 days, reevaluation was performed, which clinical improvement of clinical parameters

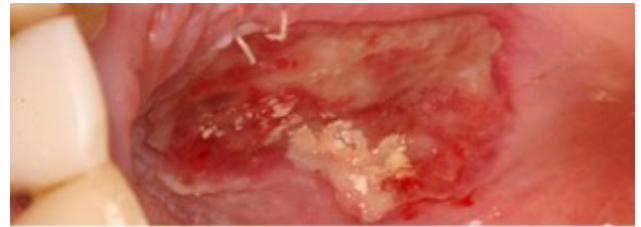


Source: The authors.

After the patient's preparation, during Surgical procedure a graft was harvested from the donor site, on palate region around upper lateral incisor to upper second premolar. The fat tissue was removed from the graft and then sutured at the recipient site with extra care to stability and adaptation to the prepared site. For protection and postoperative comfort to the patient, surgical cement was applied over both recipient and donor sites after suture.

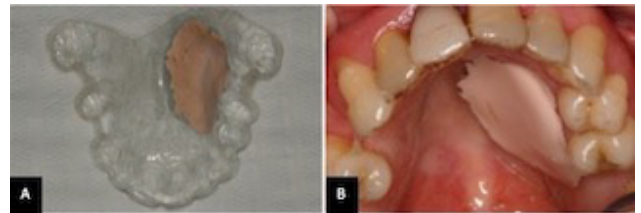
After 7 days, surgical cement and suture were removed from the donor site which showed good healing (Figure 2). However, after 2 days, the patient returned with extensive bleeding from the donor site. Bleeding was controlled by digital compression and bandage gauze. The patient reported having rinsed the mouth with hot water during shower. Due to this situation, a 1-mm thick acetate tray was readymade for comfort and the donor site protection. The tray was made with space for the surgical cement (Figure 3A and B).

**Figure 2** - After 7 days, surgical cement and suture removed from the donor site.



Source: The authors.

**Figure 3** - A. A 1-mm thick acetate tray was readymade with space for the surgical cement. B. The tray in position.



Source: The authors.

## 2.1 Discussion

As previously reported, the patient self-referred for treatment with esthetics demands and difficulty performing oral hygiene of the anterior-low arch area. After clinical exam, the patient was diagnosed with Severe Localized Chronic Periodontitis, with Class III Miller recessions on teeth 24 and 25 due to the bad bridles positioning and lack of keratinized tissue. The proposed treatment plan was basic periodontal therapy and free gingival graft to increase keratinized gingiva.

Gingival recession treatment arsenal is comprised of several different periodontal surgical techniques with the purpose of root coverage which can be achieved with proper diagnosis, surgical approach and prognosis. The interproximal papillae height, clinical attachment level and alveolar bone level are the main factors of good prognosis for root coverage<sup>3,7</sup>. In this case, surgical technique was chosen regardless of the esthetic appeal, based on the extensive gingival recession and aiming not the root coverage but the gain and maintenance of a keratinized tissue band.

The chosen approach was the free gingival graft which is a surgical technique widely used to increase the keratinized tissue width and height and also as a maneuver to relocate the frenulum and bridles<sup>1,3</sup>. Aesthetic appeal must also be taken into consideration in order to keep the patient's expectation to results according the case initial prognosis and limitations. Therefore, when esthetics is the main concern, free gingival graft from the palate must be avoided since the final result is a tissue with contrasting color and texture from the adjacent tissues. Misalignment of the mucogingival line and scar tissue are also side effects of this technique. Better results can be observed when the superficially harvest tissue provides a graft rich in collagen devoid from fat and glandular tissues<sup>3,4,8</sup>.

Pain perception after graft harvesting from palate was related in the day 01 post-op, with decreasing pain at the

subsequent days<sup>6,7</sup>. This study concluded that the harvest graft thickness is directly related to the perceived pain, the graft size was not related to pain increase<sup>9</sup>.

The extensive late bleeding that occurred in this case, generated the need of a protective apparatus for the donor site, which consisted of a 1-mm lab produced acetate tray. This device was prescribed for the patient after inadequate maintenance after 7 days post-operative when suture and surgical cement had already been removed. Protection against trauma, recurrent bleeding and pain were prevented by the use of this device.

Studies<sup>2,7,9</sup> suggest, after suture, the use of a previously made silicone tray in order to protect the surgical wound from trauma during feeding, prevent suture dehiscence and refrain swelling. However, the silicone tray causes difficulty eating due to its resilience, therefore, the acetate tray was chosen. This acetate alternative was not found in the available literature. The acetate tray was chosen for its rigid characteristic. During confection, relief was executed to provide space for surgical cement. Such device may be suggested as standard procedure to be adopted for surgeries when the donor site it to be exposed, protecting from trauma and reducing post-operative discomfort.

Among the demands presented in this case, free gingival graft was the primary surgical choice to increase keratinized tissue. Despite the patient's morbidity, hence the two surgical sites, the use of the acetate tray showed great reduction in the patient's discomfort and trauma. This approach proved to be successful since the patient described increase in self-esteem and oral hygiene facilitation which in combination contributed to satisfactory final results.

### 3 Conclusion

Among the limits of this case report, the results of this case showed that, the use of acetate tray was an effective alternative to protect the donor site. Future studies using the tray as post-

operative protocol for free gingival graft are suggested.

### References

1. Bouchard P, Malet J, Borghetti A. Decision-making in aesthetics: root coverage revisited. *Periodontology* 2000;27:97-120. doi: <https://doi.org/10.1034/j.1600-0757.2001.027001097.x>
2. Cairo F, Nieri M, Cincinelli S, Mervelt J, Pagliaro U. The interproximal clinical attachment level to classify gingival recessions and predict root coverage outcomes: a explorative and reliability. *J Clin Periodontol* 2011;38:661-6. doi: <https://doi.org/10.1111/j.1600-051X.2011.01732.x>
3. Zucchelli G, Mounssif I. Periodontal plastic surgery. *Periodontology* 2000 2015;68:333-68. doi: <https://doi.org/10.1111/prd.12059>
4. Lorenzana E, Allen E. The single-incision palatal harvest technique: a strategy for esthetics and patient comfort. *Int J Periodontics Restorative Dent* 2000;20:297-305.
5. Griffin TJ, Cheung WS, Zavras AI, Damoulis PD. Postoperative complications following gingival augmentation procedures. *J Periodontol* 2006;77(12):2070-79. doi: <https://doi.org/10.1902/jop.2006.050296>
6. Tavelli L, Ravidà A, Saleh MHA, Maska B, Del Amo FL, Rasperini G, et al. Pain perception following epithelialized gingival graft harvesting: a randomized clinical trial. *Clin Oral Invest* 2019;23:459-68. doi: [10.1007/s00784-018-2455-5](https://doi.org/10.1007/s00784-018-2455-5)
7. Burkhardt R, Hämmerle CHF, Lang NP. On behalf of the Research Group on Oral Soft Tissue Biology e Wound Healing. Self-reported pain perception of patients after mucosal graft harvesting in the palatal area. *J Clin Periodontol* 2015;42:281-7. doi: [10.1111/jcpe.12357](https://doi.org/10.1111/jcpe.12357)
8. Delima SL, Kumar PS, Tatakis DN. Bacterial community shifts during healing of palatal wounds: comparison of two graft harvesting approaches. *J Clin Periodontol* 2016;43:271-8. doi: [10.1111/jcpe.12494](https://doi.org/10.1111/jcpe.12494)
9. Ozcelik O, Seydaoglu G, Haytac CM. Diode Laser for harvesting de-epithelialized palatal graft in the treatment of recession defects: a randomized clinical trial. *J Clin Periodontol* 2016; 43:63-71. doi: [10.1111/jcpe.12487](https://doi.org/10.1111/jcpe.12487)