

# Esophageal Histopathology in Patients with Typical and Atypical Symptoms of Gastroesophageal Reflux Disease. Comparative Study with Healthy Volunteers

## Histopatologia Esofágica em Pacientes com Doença do Refluxo Gastroesofágico com Sintomas Típicos e Atípicos. Estudo Comparativo com Voluntários Sadios

Marcus Vinicius Henriques Brito<sup>a\*</sup>; Edvaldo Lima Silveira<sup>b</sup>; Ana Paula Santos Oliveira<sup>c</sup>; Rafaela de Souza Dias<sup>c</sup>; Suziane Corrêa da Silva<sup>c</sup>; Nathalya Botelho Brito<sup>c</sup>

<sup>a</sup>Pará State University, Center of Biological and Health Sciences, Department of Integrated Health, PA, Brazil

<sup>b</sup>Federal University of Pará, Health Sciences Institute, University Hospital João de Barros Barreto, PA, Brazil

<sup>c</sup>Fluminense Federal University, Center of General Studies, Biology Institute, PA, Brazil

\*E-mail: marcusbrito@amazon.com.br

Received: 17<sup>th</sup> of July 2012, Accepted: 11<sup>th</sup> of December 2012

### Abstract

The aim of this study was to investigate the histological findings in the superior, middle and inferior thirds of the esophagus of the patients porters with gastroesophageal reflux disease (GERD) that present typical and atypical symptoms as compared to volunteers without clinical manifestation of GERD. It was accomplished a prospective and longitudinal study with 30 individuals submitted to 24-hour esophageal pHmetry testing in private clinic. Among them, 20 patients presented GERD diagnostic and 10 patients presented negative results for GERD. The patients were distributed in 3 groups: Typical Reflux Group (Group I) with 10 patients with typical symptoms of GERD; Atypical Reflux Group (Group II) with 10 patients with atypical symptoms of GERD; and Asymptomatic Group (Group III): 10 volunteers without clinical manifestation of GERD. Each group was formed with 5 men and 5 women. In all patients was accomplished a esophagogastroduodenoscopy with biopsy of the superior, middle and inferior thirds of the esophagus, totalizing 3 biopsies for each patient with histological material analysis. The criteria studied were the basal cell hyperplasia, papillary zone elongation, neutrophil and eosinophil infiltration, vascular congestion and hemorrhage. The collected data were submitted to a statistics analysis by ANOVA using Bioestat<sup>®</sup> 5.0 program. The only criterion that had meaningful difference was the basal cell hyperplasia, which was more prevalent in the inferior third than the superior and middle thirds of the esophagus, for all groups. The comparative histological analysis showed only statistical differences in the inferior third of esophagus, where a significant basal layer hyperplasia was evidenced.

**Keywords:** Gastroesophageal Reflux. Esophagus. Histology.

### Resumo

*Investigar os achados histopatológicos esofágicos de biópsias nos terços superior, médio e inferior de pacientes portadores da doença do refluxo gastroesofágico (DRGE) que possuem manifestações típicas e atípicas da doença, em comparação aos voluntários sem manifestação clínica da DRGE. Foi realizado estudo prospectivo e longitudinal, estudados 30 indivíduos que realizaram pHmetria esofágica de 24h de um canal em clínica particular, sendo 20 diagnosticados com DRGE e 10 sem DRGE. Os pacientes foram distribuídos em três grupos, Grupo I: 10 pacientes com manifestações típicas de DRGE; Grupo II: 10 pacientes com manifestações atípicas de DRGE; Grupo III: 10 voluntários sem manifestação clínica da DRGE e pHmetria esofágica de 24h negativa. Cada grupo foi composto por 5 homens e 5 mulheres. Em todos os pacientes foi realizada a endoscopia digestiva alta com biópsia dos terços superior, médio e inferior do esôfago, totalizando 3 biópsias por paciente. Critérios analisados: espessamento da camada basal, elevação de papila, infiltrado neutrofilico e eosinofilico, congestão vascular e hemorragia. Não foi observada diferença estatística entre os grupos e os sexos de paciente típicos, atípicos e sem manifestações clínicas. O único critério que apresentou diferença significativa entre os terços do esôfago estudado, porém não entre os grupos do presente estudo, foi a hiperplasia da camada basal sendo mais prevalente no terço inferior em relação aos demais terços. Os dados da análise histológica comparativa realizada nos pacientes evidenciaram diferenças estatisticamente significantes somente na hiperplasia da camada basal no terço esofágico inferior.*

**Palavras-chave:** Refluxo Gastroesofágico. Esôfago. Histologia.

### 1 Introduction

The gastroesophageal reflux disease (GERD) is an infirmity with high prevalence in occident, affecting about 30% population<sup>1</sup>. In the United States, about 7% adult population complains of daily heartburn and 40% at least once a week, while in Brazil the incidence of GERD in 2001 was 48.2%<sup>2</sup>. The Brazilian Gastroesophageal Reflux Disease Consensus reaffirmed the GERD as a chronic affection caused by the retrograde flux of gastro-duodenal contents to the esophagus and/or adjacent organs, leading to a variable spectrum of symptoms and/or esophagus and/or extra-esophagus signals,

associated or not with tissues lesions<sup>3</sup>.

GERD can be manifested by typical or esophageal symptoms such as pirois and chest pain and atypical symptoms or extra-esophageal manifestations (thoracic pain, breathing and otorhinolaryngological manifestations). The typical symptoms are very characteristic of the disease, and are associated simultaneously to acid regurgitation or, most frequently, the retroesternal acid reflux sensation<sup>4,5</sup>.

More than 25 years ago, Ismail-Beigi *et al.*<sup>6</sup> described the effects of GERD in flaky mucosal of esophagus, although subsequent studies show that this findings are unspecific;

however, they remain as histological diagnosis of GERD until today<sup>7</sup>.

Only 30% patients with atypical manifestations present endoscopical evidences of GERD and more than 50% of them never presented typical symptoms such as pirois and regurgitation<sup>5,8</sup>. Aiming at investigating the differences in histological patterns in the superior, median and inferior third of esophagus, the objective of this research is to study esophagus histopathological findings in GERD patients with typical and atypical manifestations, as compared to those individuals without clinical manifestation.

## 2 Material and Methods

All the patients were studied under the Helsinki Declaration and Nuremberg Code precept, respecting the Human Being Research Normative (Res. CNS 196/96) of National Health Counsel, approved by the Research Ethics Committee (115/06 protocol revalidated in 2009) of Federal University of Pará, after the authorization of both Unigastro Clinic Directory and patients or their legal representative, by a consent term free and clarified.

It was performed a prospective and longitudinal study with a total of 30 patients, 20 of them admitted in a private Clinic with GERD diagnosis and 10 individuals without any complain. Each studied group presented 5 men and 5 women. The diagnosis method used to define the disease was one-channel 24h esophageal pHmetry, using a Alacer AL-III® pHmeter, with the DeMeester score.

The three studied groups were:

Typical Reflux Group (Group I): 10 patients with at least one of the typical manifestations of GERD (pirosis or regurgitation) without other symptoms;

Atypical Reflux Group (Group II): 10 patients with at least one of atypical manifestations of GERD (chest pain, airways and otorhinolaryngological problems) without other symptoms;

Asymptomatic Group (Group III): 10 volunteers without any high digestive clinical manifestation.

### The inclusion criteria used in this study were:

#### For all patients:

- must be 18 - 45 years old.

#### For the group with typical and atypical symptoms:

- Present GERD previously diagnosed by pHmetry.
- Present pathological daily type reflux.
- Not using Proton pump inhibitors (PPI) for at least 15 days before the esophageal biopsies by high digestive endoscopy.

#### For the group with no manifestation of GERD (volunteers):

- must be apparently healthy.
- Must present no clinical characterization of GERD in the last year and
- One channel 24h esophageal pHmetry negative.

### Patient Selection:

After elucidation and subscription of Free and Clarified

Consent Term, the patients performed a high digestive endoscopy, using Pentax videoendoscopy EPM-3000. All patients were submitted to biopsies of the superior, medium, inferior esophageal third, which were performed at 15, 10 and 5 cm from esophageal-gastric transition, with 3mm fragments.

It was collected samples from anterior region of each esophageal third, totalizing 3 biopsies for each patient. The samples were taken to the private laboratory and submitted to histological routine processing and hematoxylin and eosine staining (HE).

In the histological evaluation of the biopsies, the presence and intensity of the inflammatory process were analyzed by the histopathological criteria for esophagitis<sup>8</sup> as described below, beyond the presence of vascular congestion and hemorrhage:

- Basal layer hyperplasia in relation to total epithelial depth (absent: until 15%; light: 15-33%; moderate: 33-67%; severe: up to 67%).
- Elevation of papilla in relation to total epithelial depth (absent: 0-67% or present: up to 67%).
- Neutrophils and eosinophils infiltrated in relation to the greater visualized field (absent: 0; light: 1-2 per field; moderate: 3-10 per field; severe: up to 10 per field).

There was only one observant for each diagnostic method used. The endoscopist was not informed about the clinical details of the patient, and the pathologist was not informed about the endoscopic diagnosis.

The histopathological criteria received scores equivalent to presence, absence or alteration level. The scores were 1 (absence), 2 (light), 3 (moderated) and 4 (severe), with exception of the papilla elevation criteria, vascular congestion and hemorrhages, which received scores 1 and 2 for presence and absence, respectively.

Collected data were disposed on Microsoft Excel® 2003 and the statistical analysis was performed by Bioestat® 5.0.

According to the variables, a comparative statistical analysis was performed using ANOVA test, at 5% ( $\alpha \leq 5$ ) significance level for nullity hypothesis refusal, and the significant results were marked with a (\*).

## 3 Results and Discussion

No patients or volunteer presented abnormal endoscopic results or was in use of PPI at least 90 days before performing the exams selected to this study.

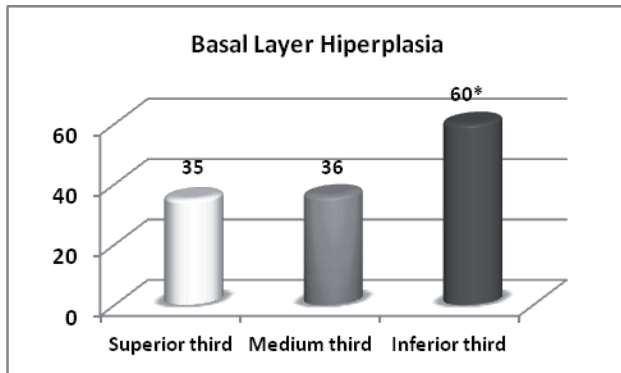
No histopathological criteria studied (vascular congestion and hemorrhage, papillary zone elongation, total epithelial depth, elevation of papilla in relation to total epithelial depth, neutrophils and eosinophils infiltrated) presented significant differences, neither between esophageal thirds nor among reflux group and patients with no clinical manifestations of GERD.

In basal layer hyperplasia no difference among the patients groups was observed ( $P = 0.6149$ ). However, there was statistical difference in the inferior third as compared to the others, ( $P = 0.0046$ ) (Table 1, Figure 1).

**Table 1:** Basal layer hyperplasia degree in the superior, medium and inferior esophagus third of typical, atypical GERD and asymptomatic patients studied in private Clinic.

	Basal Layer Hyperplasia						Total
	Group I		Group II		Group III		
	men	women	men	Women	men	women	
<b>Superior</b>	6	5	5	7	5	7	<b>35</b>
<b>Medium</b>	6	6	5	6	7	6	<b>36</b>
<b>Inferior</b>	12	6	6	10	14	12	<b>60*</b>
<b>Total</b>	<b>24</b>	<b>17</b>	<b>16</b>	<b>23</b>	<b>26</b>	<b>25</b>	
<b>Total</b>	<b>41</b>		<b>39</b>		<b>51</b>		

Group I x Group II x Group III (ANOVA) P = 0,6149  
 Superior x Medium x Inferior (ANOVA) P = 0,0046



**Figure 1:** Basal layer hyperplasia according to esophageal thirds Superior x Medium x Inferior (ANOVA) P = 0,0046

Gastroesophageal reflux disease (GERD) is an infirmity with high prevalence in west, affecting about 30% of population.<sup>1</sup>

Due to different clinical presentations of GERD, it was thought relevant to verify the existence of differences in histopathological patterns between daily reflux patients, typical and atypical manifestation and patients with no clinical manifestation of GERD, comparing the superior, medium and inferior esophageal thirds to identify histological characteristics that justify the different manifestations.

Góes-Júnior and Brito<sup>9</sup> observed that 46% patients with GERD submitted to pHmetry presented daily-type reflux. Thus, this group was chosen for the study due to the high prevalence of the disease and for achieving a more homogenous sample, once the others reflux types (nocturnal and mixed) presented higher levels of aggression in esophageal mucosa. Flora-Filho *et al.*<sup>10</sup> demonstrated that there is a tendency to great tissues alterations in patients with more severe patterns of reflux (nocturnal and mixed), in comparison to daily reflux.

It believed that the higher prevalence of hyperplasia of inferior third of basal layer, as observed in this study (Table 1, Figure 1) is due to the more frequent and intense acid aggression in the inferior third in comparison to the other thirds. The tissue develops adaptive mechanisms as higher levels of cellular renovation evidenced by basal layer density and papilla extension through the raise of nutrient flux to

reminiscent cells<sup>10,11</sup>.

About the inflammatory process, present research presented no significant difference in esophageal thirds damage between the groups, once it was expected that the atypical patients present a higher damage on their medium and superior esophageal third.

From patients with no clinical manifestations, it was expected lower intensity of the alterations; however, it was observed as frequent and intense alterations as the patients with GERD. The study of Shehry<sup>12</sup> observed that the presence and severity of extra-esophageal manifestations are no related to the level of esophageal involvement.

According to Quatu and Triadafilopoulos<sup>13</sup> the intensity and the symptoms frequency of GERD are weak predictive factors of the presence and/or severity of esophagitis. This fact corroborates with the results of this study for the patients without clinical manifestations of reflux disease, once the majority of histopathological criteria presented equal or higher scores than the patients with confirmed diagnosis of GERD through pHmetry.

In a study performed by Bowrey *et al.*<sup>7</sup> it was not possible to confirm the value of histological alterations on flaky esophageal mucosa as markers of gastroesophageal reflux in patients with non erosive reflux disease, similarly to the finding of the present study, where the patients with GERD also presented the non erosive form, once no alteration was observed through endoscopy.

At present, it is patent in the literature that patient with typical GERD presents greater incidence of histopathological inflammatory findings in the inferior esophagus, while in the atypical cases, these findings are more frequent in superior esophagus and pharynx<sup>14</sup>. However, this was not observed in the present study.

It was also evidenced that in GERD the lesions are more severe next to the Z-line, which were expressed proximally in the esophagus and in a more intense way in patients with erosive illness in relation to those with non-erosive illness<sup>15</sup>. In addition, the laparoscopic fundoplicature or continuous therapy with PPI are associated with significant and similar improvement in microscopic esophagitis after 1-year treatment that is kept for 3 years<sup>16</sup>.

Some factors have not been elucidated yet, such as those that lead to these different histopathologic behaviors in typical and atypical patients; the reasons why many patients with GERD symptoms such as thickness, chronic cough and no cardiac precordial pain had never related pirosis or regurgitation episode; the reasons why patients with serious erosive lesions of inferior esophagus had never presented breathing, pharyngical, otorhinolaryngological manifestations or thoracic pain.

The majority of the findings in literature presented similar results to this study, with no correlation between the pHmetry and histopathological findings<sup>11</sup>.

However, two studies did not corroborate the findings of the present study. The first one, reported by Johnson<sup>17</sup> found significant correlation among the acid exposition of esophagus and both papilla elevation and basal layer hyperplasia, however the correlation coefficient was low, not exceeding 0.33. In the other study, Schindlbeck *et al.* found a minimal histological difference between the patients with GERD and the healthy patients.

The comparative histopathological study of esophagus have not evidenced alterations between the esophagus thirds, consequently it is not possible to justify the several manifestations of the disease. The studies on literature show that GERD is truly a complex disease, because in most cases there is no correlation between the diagnostic techniques or in relation to the symptomatology presented by the patients.

Thus, it believes that the study of the esophageal epithelium in patients with GERD probably will develop to molecular level. Flora-Filho *et al.*<sup>10</sup> propose that subtle of protean expression should classify with more sensibility the cellular lesion intensity.

Furthermore, together with the histology study, the esophageal protection factors such as salivary volume, salivary bicarbonate, and esophageal mucus could be investigated, as well as others factors that could be the differential between a typical and atypical manifestation.

## 5 Conclusion

The comparative histological analysis of the three thirds of the esophagus (superior, middle and inferior) carried out in patients with typical and atypical DRGE, in relation to the asymptomatic patients, evidenced statistical differences only in the basal layer hyperplasia.

## References

1. Domingues GR, Mendonça A. Doença do refluxo gastroesofágico: qual o melhor método diagnóstico? *In*: Alves JG. Temas de atualização em gastroenterologia. Rio de Janeiro: Trasso; 2005. p.132-3.
2. Oliveira SS, Santos IS, Silva JFP, Machado EC. Prevalência e fatores associados à doença do refluxo gastroesofágico. *Arq Gastroenterol* 2005;2(42):116-21.
3. Moraes Filho JPP, Meneghelli U, Boaventura S, Leitão O, Ferrari Junior AP, Almeida JR, *et al.* Efficacy and tolerability of pantoprazole versus ranitidine in the treatment of reflux esophagitis and the influence of *Helicobacter pylori* infection on healing rate. *Dis Esophagus* 2002;1(15):50-6.
4. Lemme EMO. Manifestações atípicas da Doença do Refluxo Gastroesofágico. *In*: Alves JG. Temas de atualização em gastroenterologia. Rio de Janeiro: Trasso; 2005. p.143-9.
5. Jaspersen D. Extra-esophageal disorders in gastroesophageal reflux disease. *Digest Disease* 2004(22):115-9.
6. Ismail-Beigi F, Horton PF, Pope II CE. Histological consequences of gastroesophageal reflux in man. *Gastroenterology* 1970;58(2):163-74.
7. Bowrey DJ, Williams GT, Clark GWB. Histological changes in the oesophageal squamous mucosa: correlation with ambulatory 24 hour pH monitoring. *J Clin Pathol* 2006(56):205-8.
8. Pasha SF, Dibaise JK, Kim HJ, De Petris G, Crowell MD, Fleischer DE. Patient characteristics, clinical, endoscopic, and histologic findings in adult eosinophilic esophagitis: a case series and systematic review of the medical literature. *Dis Esophagus* 2007;4(20):311-9.
9. Góes Júnior AMO, Brito MVH. Correlação diagnóstica entre endoscopia, manometria e pHmetria esofágica de 24 horas na Doença do refluxo Gastroesofágico. *Rev Para Med* 2005;19(2):25-34.
10. Flora-Filho R, Câmara-Lopes LH, Zilberstein B. Critérios histológicos de esofagite na doença do refluxo gastroesofágico. Reavaliação da sensibilidade da pHmetria esofágica de 24 horas. *Arq Gastroenterol* 2000;4(37):197-202.
11. Narayani RI, Burton MP, Young GS. Utility of esophageal biopsy in the diagnosis of nonerosive reflux disease. *Dis Esophagus* 2003;3(16):187-92.
12. Shehry AM. Clinical review of otolaryngologic manifestations of gastroesophageal reflux disease. Brief review. *Annals of Saudi Medicine* 2000;5/6(20):409.
13. Quatu LR, Triadafilopoulos G. Complete elimination of reflux symptoms does not guarantee normalization of intraesophageal acid reflux in patients with Barrett's esophagus. *Am J Gastroenterol* 1998(93):711-6.
14. Wada T, Sasaki M, Kataoka H, Ogasawara N, Kanematsu T, Tanida S, *et al.* Gastroesophageal and laryngopharyngeal reflux symptoms correlate with histopathologic inflammation of the upper and lower esophagus. *J Clin Gastroenterol* 2009;3(43):249-52.
15. Mastracci L, Spaggiari P, Grillo F, Zentilin P, Dulbecco P, Ceppà P, *et al.* Microscopic esophagitis in gastro-esophageal reflux disease: individual lesions, biopsy sampling, and clinical correlations. *Virchows Arch* 2009;1(454):31-9.
16. Fiocca R, Mastracci L, Engström C, Attwood S, Ell C, Galmiche JP, *et al.* Long-term outcome of microscopic esophagitis in chronic GERD patients treated with esomeprazole or laparoscopic antireflux surgery in the LOTUS trial. *Am J Gastroenterol* 2010;5(105):1015-23.
17. Johnson LF, Demeester TR, Haggitt RC. Esophageal epithelial response to gastroesophageal reflux. *Dig Dis Sci* 1978(23):498-509.
18. Schindlbeck NE, Wiebecke B, Klausner AG, Voderholzer WA, Muller-Lissner SA. Diagnostic value of histology in non-erosive gastro-oesophageal reflux disease. *Gut* 1996(39):151-4.