

Supranumerário: a Importância do Tratamento Ortodôntico Precoce

Supernumerary: the Importance of Early Orthodontic Treatment

Flaviana Alves Dias^a; Lucineide Lima dos Santos^a; Marcio Rodrigues de Almeida^a; Ana Cláudia de Castro Ferreira Conti^a; Paula Vanessa Pedron Oltramari^a; Thais Maria Freire Fernandes^{*a}; Renato Rodrigues de Almeida^a

^aUnopar, Stricto Sensu Graduate Program in Dentistry. PR, Brazil.

*E-mail: thaismaria@hotmail.com

Recebido em: 08/10/2018

Aprovado em: 18/12/2018

Abstract

The presence of supernumeraries may lead to irruptive problems, such as impacted teeth, functional and aesthetic disorders. The present study describes two clinical cases, with anterior teeth eruption disorders caused by additional dental elements, treated early. Patients presented with aesthetic involvement, with delay in the emergence of the upper incisors. The clinical and radiographic examinations detected the presence of obstacles to the teeth eruption. Early treatment with 2x4 appliance was realized, followed by final corrective orthodontics. After restoration of the dimension for retained teeth, there was spontaneous eruption in clinical case 1 and need of traction in clinical case 2. When patients reached the complete permanent dentition, a corrective phase was performed with the objective of detailing the dental occlusion and finishing the treatment. The early diagnosis of teeth impacted and supernumerary, provide the achievement of adequate occlusion and positive aesthetic of patients, with good prognosis, avoiding psychological and functional problems caused by absence of anterior teeth.

Keywords Interceptive Orthodontics. Supernumerary Tooth. Ectopic Tooth Eruption.

Resumo

A presença de supranumerários pode ocasionar problemas irruptivos, como impacção de dentes, desordens funcionais e estéticas. O presente trabalho descreve dois casos clínicos abordados precocemente, com alterações na irrupção de dentes anteriores devido a presença de supranumerários. Os pacientes apresentavam queixas estéticas, com atraso no aparecimento dos incisivos superiores. Os exames clínico e radiográfico detectaram a presença de barreiras irruptivas. Realizou-se tratamento precoce com auxílio da mecânica 4x2, seguido pela ortodontia corretiva final. Após etapa de restabelecimento da dimensão para os dentes retidos, houve irrompimento espontâneo no caso clínico 1 e necessidade de tracionamento no caso clínico 2. Quando pacientes atingiram a dentição permanente completa, realizou-se uma fase corretiva com o objetivo de detalhamento da oclusão dentária e finalização do tratamento. O diagnóstico precoce de impacção dentária e detecção de supranumerários favoreceu a restituição de oclusão adequada e estética dos pacientes, com prognóstico muito favorável, evitando problemas psicológicos e funcionais provocados pela ausência de dentes anteriores.

Palavras-chave: Ortodontia interceptora. Dente supranumerário. Erupção ectópica de dente.

1 Introduction

The diagnosis of alterations and preventing the installation of malocclusions requires constant discipline and surveillance of patients and dentists for the maintenance of the normal development of the dental arches^{1,2}. To prevent greater complexity of occlusal changes, the identification and early treatment of irruptive disorders are required. Diagnostic examinations, such as the panoramic radiography, present themselves as promoters of detection of dental disorders, such as the presence of supernumerary teeth or odontomas³.

When there is a number of teeth that exceed the normal it is called supernumerary teeth, are more frequent in the permanent dentition, with predominance in the maxilla^{2,4}. The main theories of the origin of these phenomena are based on formation originated from remnants of the dental lamina, the hyperactivity of the same, that would lead to additional number of dental germs or the dichotomy of a tooth in development³.

The location of these elements in the anterior region of the maxilla, causes the impaction of upper incisors, aggravating, consequently, the aesthetic and functional impairment^{5,6}. Several conducts can be proposed for the treatment, according to the position and number of teeth and from the time of diagnosis^{3,7}, requiring surgical and/or orthodontic intervention^{2,8,9}.

This article proposes to present two cases of patients in the stage of mixed dentition, with the presence of supernumerary teeth in the anterior region, intercepted with the aid of fixed orthodontics.

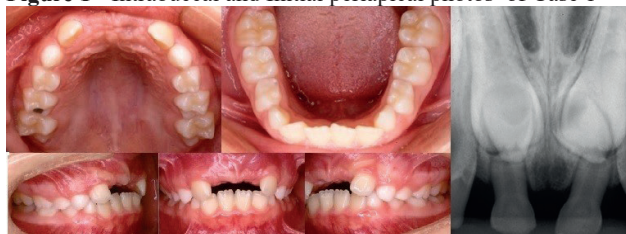
2 Case Study

2.1 Clinical Case 1

Patient aged 8 years and 3 months old, male sex, sought treatment with main complaint of delay in the eruption of central incisors teeth. Upon the initial clinical examination, it

was discovered mesofacial standard, profile slightly convex, molar relation Class I, irruption of permanent lateral and absence of central incisors. At the radiographic examination, it was observed blockade of the irruption of the central incisors caused by two supernumerary included teeth, with loss of space in the anterior region and aesthetic impairment (Figure 1).

Figure 1 - Intra-buccal and Initial periapical photos of Case 1

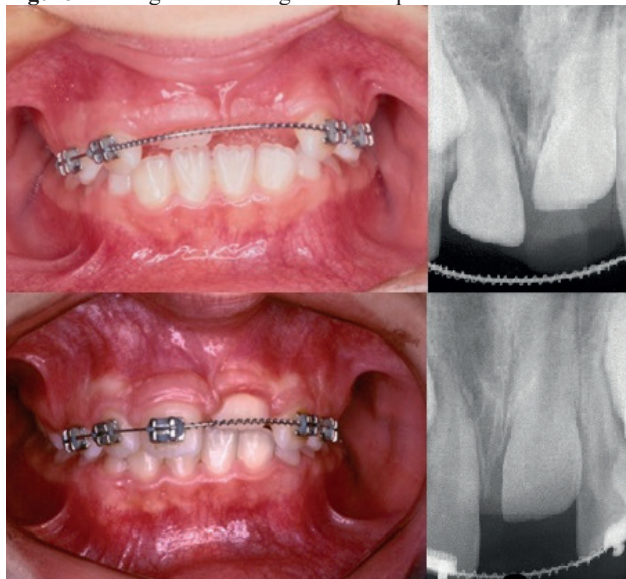


Source: The authors.

The proposed treatment plan consisted of two stages: the first interceptor, aiming at recovery of anterior space, with mechanical 4x2, and removal of supernumerary teeth; and the second corrective, for occlusal detailing and completion of treatment.

The treatment was started with installation of brackets on the teeth 12, 53, 22, 63, and arcs of alignment and leveling 0.016" nickel-titanium, followed by the 0.018" open spring steel with nickel-titanium in the anterior region and extraction of supernumerary teeth. After 6 months, there was a spontaneous irruption of tooth 11, subsequently included in the mechanics, keeping spring open to conserve space for the tooth 21 (Figure 2).

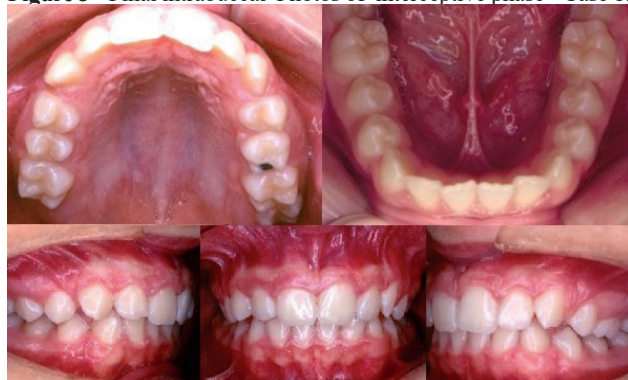Figure 2 - Images illustrating the development of Case 1.



Source: The authors.

With complete eruption of teeth included and alignment of the same, completed the first phase of treatment after 1 year and 4 months (Figure 3).

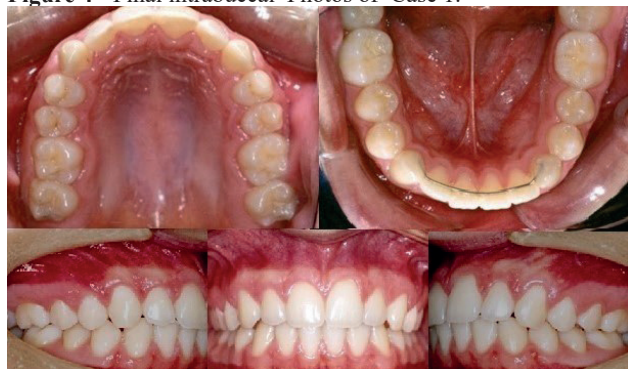Figure 3 - Final intra-buccal Photos of interceptive phase - Case 1.



Source: The authors.

The patient returned after 4 years (13 years and 1 month of age), with the complete permanent dentition, for the second phase of the treatment with fixed mechanics for the occlusion refinement. At 15 years and 4 months, it is noticed the excellent final result (Figure 4).

Figure 4 - Final intra-buccal Photos of Case 1.

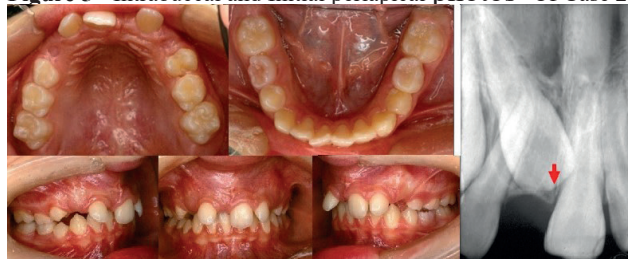

Source: The authors.

2.2 Clinical Case 2

9-year-old female patient sought for services due to complaint of delay in the irruption of the central incisor. Upon clinical exam, it was detected mesofacial standard profile slightly convex, molar relation Class II, Division 2, subdivision right, mixed dentition, absence of right irrupted central incisor (11). When observing the case radiographically, it was noted odontoma in the region of the tooth 11, with loss of space in the region, blocking the irruption of the same (Figure 5).

Figure 5 - Intra-buccal and Initial periapical photos Of Case 2



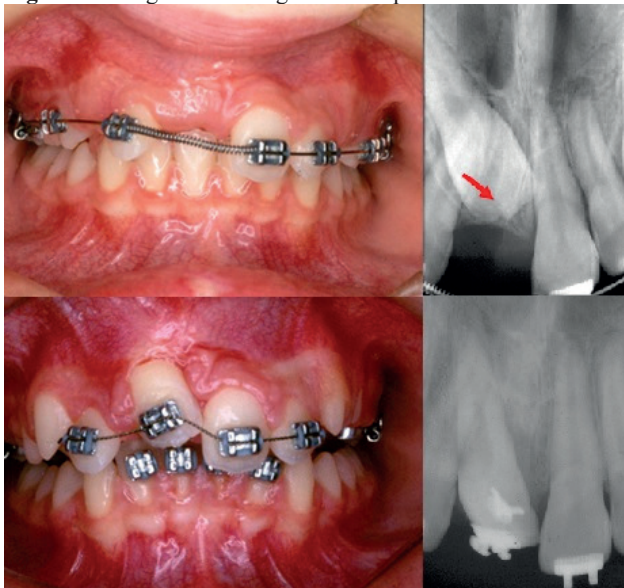
Source: The authors.

After careful evaluation, it was planned to become the treatment of the patient in two stages: the first interceptor, with

the use of a fixed device, 4x2, with springs open to recovery of space, extraction of the \supernumerary teeth and traction of tooth 11; and the second corrective, for final detailing of the case.

The bonding of brackets on teeth 14,12,21,22,64 and 65 , bands in 16 and 26, and arcs of alignment and leveling 0.016” nickel-titanium steel, followed by the 0.018” steel with spring open of nickel-titanium in the region of the tooth 11, corresponded to the first steps of treatment. After 4 months, with recovery of the space for the impacted tooth, we carried out the removal of odontoma and bonding of devices on the buccal and palate for pulling the same, which was angled and there was no possibility of a spontaneous eruption. For the traction of tooth 11, force was exerted by vestibular and palate, with the aid of intermaxillary elastic bands supported by brackets bonded to the teeth 32,31,41,42, to prevent dental tilt. It was concluded this first stage after 1 year and 2 months (Figure 6).

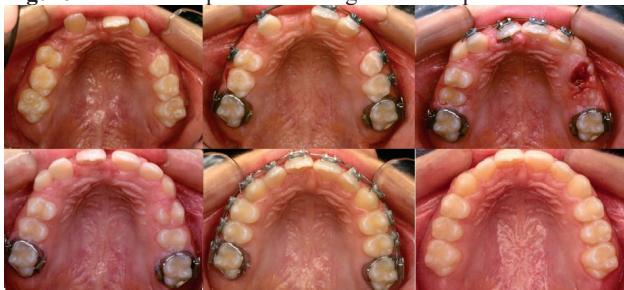Figure 6 - images illustrating the development of Case 2.



Source: The authors.

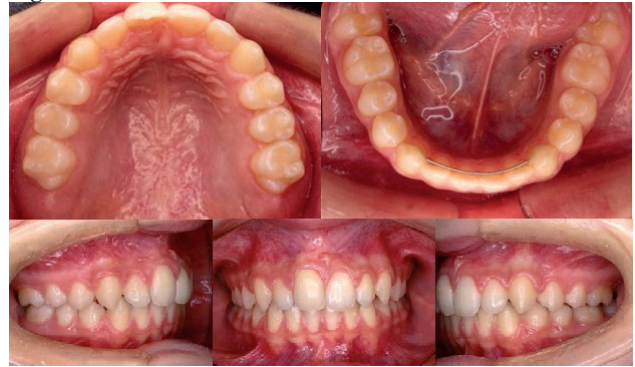After one year, upon achieving the permanent dentition, it was performed a corrective phase with mechanical fixing and the treatment of the patient was completed , with successful results, to 12 years and 10 months of age (Figures 7 and 8).

Figure 7 - Occlusal photos showing the development of case 2



Source: The authors.

Figure 8 - Final intrabuccal Photos of Case 2.



Source: The authors.

3 Conclusion

The early diagnosis of dental impaction and detection of supernumerary teeth and odontoma in the anterior region, through clinical and radiographic examination , favored the return of adequate occlusion and aesthetics of patients, with a very favorable prognosis, avoiding functional and psychological problems caused by the absence of anterior teeth.

References

1. Garvey MT, Barry HJ, Blake M. Supernumerary teeth--an overview of classification, diagnosis and management. *J Can Dent Assoc* 1999;65(11):612-6.
2. Leco Berrocal MI, Martin Morales JF, Martinez Gonzalez JM. An observational study of the frequency of supernumerary teeth in a population of 2000 patients. *Med Oral Patol Oral Cir Bucal* 2007;12(2):E134-138.
3. Almeida LMOH, Kitabayashi S, Noronha JH. Fechamento de diastema interincisivos utilizando placa com molas após a exodontia de mesiodens. *Rev Clín Ortod Dental Press* 2012;11(3):54-8.
4. Ashkenazi M, Greenberg BP, Chodik G, Rakocz M. Postoperative prognosis of unerupted teeth after removal of supernumerary teeth or odontomas. *Am J Orthod Dentofacial Orthop* 2007;131(5):614-9.
5. Chaushu S, Becker T, Becker A. Impacted central incisors: factors affecting prognosis and treatment duration. *Am J Orthod Dentofacial Orthop* 2015;147(3):355-62. doi: 10.1016/j.ajodo.2014.11.019.
6. Chaushu S, Zilberman Y, Becker A. Maxillary incisor impaction and its relationship to canine displacement. *Am J Orthod Dentofacial Orthop* 2003;124(2):144-50.
7. Salcido JF, Ledesma C, Hernández F, Pérez D, Garcés M. Frecuencia de dientes supernumerarios en una poblacion Mexicana. *Med Oral Patol Oral Cir Bucal* 2004;9:403-9.
8. Dehdashti M, Gugny P. A propos des polyodonties, proposition d'une approche thérapeutique. *Rev Orthop Dento Faciale* 1990;24(4):465-71.
9. Zilberman Y, Malron M, Shteyer A. Assessment of 100 children in Jerusalem with supernumerary teeth in the premaxillary region. *ASDC J Dent Child* 1992;59(1):44-7.