

## Efetividade em Longo-Prazo de Dois Aparelhos Intraorais no Tratamento da Apneia Obstrutiva do Sono: Relato de um Caso

### Long-Term Effectiveness of Two Oral Appliances for Obstructive Sleep Apnea: a Case Report

Maria de Lourdes Rabelo Guimarães<sup>a</sup>; Júlia Barbosa Becattini Pereira<sup>b</sup>; Flávia Fulgêncio Tanure Jardim<sup>b</sup>; Tamires Monteiro Martins da Costa<sup>b</sup>; Paulo Renato Becattini<sup>a</sup>; Ana Paula Hermont<sup>c\*</sup>

<sup>a</sup>Federal University of Minas Gerais, Faculty of Dentistry, MG, Brazil

<sup>b</sup>Pontifical Catholic University of Minas Gerais, Faculty of Dentistry, MG, Brazil

<sup>c</sup>Federal University of Minas Gerais, Faculty of Dentistry, Department of Pediatric Dentistry and Orthodontics, MG, Brazil

\*E-mail: polinha1987@yahoo.com

Recebido: 08 de julho de 2014; Aceito: 05 de outubro de 2014

#### Resumo

A síndrome da apneia obstrutiva do sono - SAOS é um distúrbio respiratório caracterizado por episódios recorrentes de obstrução das vias aéreas superiores durante o sono. Aparelhos intraorais - AIOs têm sido utilizados em pacientes com SAOS moderada ou severa que não se adaptaram ou recusam o tratamento com pressão positiva contínua nas vias aéreas - CPAP ou pacientes com impossibilidade de realização de cirurgia. Aparelhos de avanço mandibular têm sido amplamente utilizados com eficácia. Além de estabilizar a mandíbula, alguns AIOs permitem que o paciente faça movimentos mandibulares de lateralidade e verticais sem desencaixar o aparelho, reduzindo o risco de lesionar a articulação temporomandibular. O objetivo desse estudo foi avaliar a efetividade de dois tipos de AIO no tratamento da apneia. Este estudo apresenta o caso de um paciente com SAOS moderada e grave dessaturação de oxigênio (SaO<sub>2</sub> mínima de 55%), tratado com dois tipos de aparelho intraoral: o PM Positioner<sup>TM</sup>, que não permite movimentos laterais da mandíbula, e a Placa Lateroprotrusiva (PLP<sup>®</sup>), que permite movimentos de lateralidade. O aparelho PLP<sup>®</sup> foi mais efetivo se comparado ao PM Positioner. Através da avaliação em longo prazo observou-se que o PLP<sup>®</sup> proporcionou mais conforto ao paciente, maior aderência ao tratamento e uma maior capacidade de avanço mandibular, quando comparado ao aparelho que não permitia movimentos mandibulares de lateralidade.

**Palavras-chave:** Apneia do Sono Tipo Obstrutiva. Avanço Mandibular. Desempenho de Aparelho Ortodôntico.

#### Abstract

*Obstructive sleep apnea syndrome (OSAS) is a breathing disorder characterized by recurrent episodes of upper airway obstruction during sleep. Oral appliances have been used in patients with moderate to severe OSAS, who cannot tolerate or refuse the therapy with continuous positive airway pressure or candidates who present impossibility of performing surgery. Oral appliances such as mandibular advancement devices (MADs) have been widely used and proven to be effective. In addition to stabilizing the mandible, some MADs allow the patient to move it laterally and vertically without disengaging the appliance, reducing the risk of injuring the temporomandibular joint. The aim of this study was to evaluate the effectiveness of two types of oral appliances in the treatment of apnea. A patient who presented moderate OSAS and severe oxygen desaturation (SaO<sub>2</sub> minimum of 55%) was treated by two different types of MADs: the PM Positioner<sup>TM</sup>, which is a device that do not allow lateral movements of the mandible, and the Placa Lateroprotrusiva (PLP<sup>®</sup>), which allows lateral movements. The PLP<sup>®</sup> was more effective than the PM Positioner<sup>TM</sup>. Long-term assessment revealed that PLP<sup>®</sup> was more effective because it provided more comfort and a greater capacity for mandibular advancement, when compared to a device which did not allow the jaw to move laterally.*

**Keywords:** Sleep Apnea. Obstructive. Mandibular Advancement. Orthodontic Appliance Design.

#### 1 Introduction

Obstructive sleep apnea syndrome - OSAS is a breathing disorder characterized by recurrent episodes of partial or complete obstruction of the upper airway during sleep, which leads to intermittent hypoxemia, transient hypercapnia and frequent arousals, associated with signs and/or clinical symptoms<sup>1</sup>. The signs and symptoms of OSAS are commonly described as excessive sleepiness, snoring, presence of respiratory pauses during sleep, cognitive impairment, cardiovascular disease, anxiety, depression and metabolic dysfunction<sup>2-8</sup>.

Polysomnography is usually required when diagnosing OSA among adults, once it indicates the disorder's severity, and supports the treatment planning<sup>1</sup>. The classification of

OSAS's severity depends on both the degree of daytime sleepiness and the apnea-hypopnea index - AHI, which refers to the total number of complete cessations (apnea) and partial obstructions (hypopnea) of breathing occurring per hour of sleep<sup>1,5,9,10</sup>.

A recent study in Brazil has shown that 55% of the population of São Paulo suffers from sleepiness, fatigue (38.9%), snoring (20.5%), while 29.2% reported breathing interruption. The research found an average of 32.8% of the participants with OSAS<sup>5</sup>.

Oral appliances are one of the clinical approaches for the treatment of OSAS<sup>11</sup>. They are used during sleep to prevent both the tissues of the oropharynx, and the base of the tongue from collapsing and causing airway obstruction<sup>12-14</sup>. The

OAs are indicated for patients who present primary snoring or have mild OSAS, who do not respond or are not suitable for treatment with behavioral measures such as weight loss or changes in sleep position. Moreover, OAs are advised for patients with moderate to severe OSAS who cannot tolerate or refuse the continuous positive airway pressure - CPAP therapy, or candidates who present impossibility of performing surgery<sup>11,15,16</sup>.

Basically, there are four models of OAs: tongue retainers devices (TRD), mandibular advancement devices - MADs, adjustable soft palate lifter - ASPL, and oral positive airway pressure devices<sup>17-19</sup>. However, most devices are designed to be MADs<sup>20</sup>, and presented the best results when treating OSAS<sup>20,21</sup>, once they modify the upper airway by changing the posture of the jaw and tongue<sup>8,11,22,23</sup>.

The category of MADs can be subdivided into adjustable or non-adjustable and classified according to the manufacturing method; prefabricated or made in the laboratory. The material used in manufacturing can be hard or soft, and the retention can be in the maxilla or in both arches<sup>15,24</sup>. Besides stabilizing the jaw, some MADs allow lateral movements, retraction, protrusion and opening up, therefore they reduce the risk of injuring the temporomandibular joint - TMJ, increasing comfort and the patient adherence to treatment<sup>25-27</sup>.

There is a relatively limited number of trials comparing the efficacy of customized OAs designs. Nevertheless, the literature suggests that different designs are similarly effective in treating OSA<sup>28</sup>. This study presents a case of a patient with moderate OSAS (16.2 / h), with significant oxygen desaturation (SaO<sub>2</sub> minimum of 55%) treated by two types of MADs: the PM Positioner™<sup>29</sup> and *Placa Lateroprotrusiva* (PLP®). The patient was assessed and monitored in the long term. An informed consent form explaining the purpose of the study and requiring the written consent was given to the patient. The patient agreed with the study and the consent form was properly signed.

## 2 Case Report

The patient, female, 59 years old, was referred by an otorhinolaryngologist after the resection of enlarged uvula. The patient's main concern was to reduce the persistent fatigue and sleepiness. During anamnesis, the patient reported having already used an oral appliance for three years, but had to discontinue the treatment due to joint pain. The patient presented Epworth sleepiness score<sup>30</sup> of 14, and body mass index (BMI)<sup>31</sup> of 31.2 Kg/m<sup>2</sup>.

### 2.1 Clinical examination

During dental examination, the morphological analysis of the face in frontal and lateral views was classified as pattern I, which is characterized by the normal sagittal and vertical skeletal relationships. The patient had apparent symmetry in front view, and presented convexity in the face similar to

the pattern I of normality in lateral view<sup>32</sup>. The mandibular movement was performed in a coordinated manner and the intraoral examination showed a mandibular midline shift to the left, of 1 mm, Class III canine relationship on the left side, and Class I on the right<sup>33</sup>. According to Angle's classification<sup>33</sup>, the patient presented an occlusion, classified as class I or neutroclusion on both sides. A posteriorized soft palate<sup>10</sup>, macroglossia<sup>10</sup>, Mallampati grade IV<sup>10</sup>, and tonsil grade II was also detected<sup>10</sup>.

## 3 Results and Discussion

### 3.1 Polysomnography

AHI index was defined as the number of episodes of apnea plus episodes of hypopnea per hour of sleep<sup>10</sup>. OSA was defined as AHI > 5.40. The baseline polysomnography showed an apnea index (AI) of 9.7 / h, hypopnea index (HI) of 6.5 / h, with an AHI of 16.2 / h<sup>10</sup>. The average oxygen saturation was 86% and minimum 55%<sup>10</sup>. The percent of total sleep time below 90% saturation was 99.5%, a sleep efficiency of 81%, N3 sleep time of 7%, REM of 18% and the awakening index of 35.6 / h<sup>10</sup>.

### 3.2 Radiographic analysis

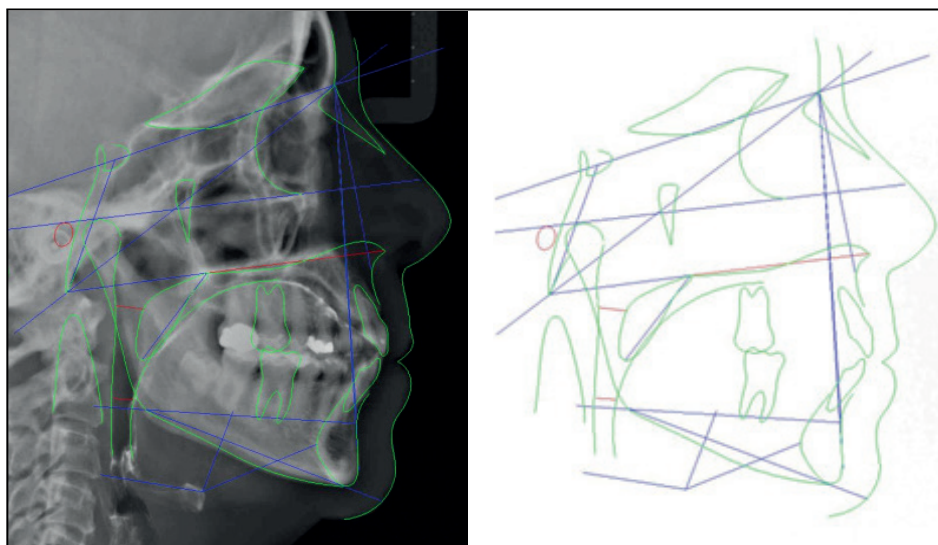
Digital panoramic radiographic analysis revealed absence of carious lesions. There were 28 erupted teeth and one impacted tooth (lower right 3<sup>rd</sup> molar), absence of upper 3<sup>rd</sup> molars and lower left 3<sup>rd</sup> molar. It was also noticed the absence of apical lesions, thickening or enlargement of the periodontal space. There was generalized loss of interdental bone crest (maxilla and mandible). Condyles and condylar eminences were normal<sup>34</sup>.

### 3.3 Cephalometric analysis

Since the 1980s, cephalometry can be used as a complementary test in patients with OSAS to assist in the identification of craniofacial anatomical determinants involved in pharyngeal collapse during sleep. The cephalometry in lateral view is relatively easy to analyze, low-cost, and emits minimal radiation levels, offering a two-dimensional visualization of anatomic structures<sup>35</sup>.

Despite the difficulty of comparison, some characteristics are typical in patients with OSAS. These characteristics include the increase in the length of the soft palate, thicker soft palate, reduced amplitude of the pharyngeal airway space, micrognathia, retroposition of the maxilla or mandible, and alterations in the hyoid bone position. Some other anatomical factors may contribute to the obstructive process of the upper airway during sleep, including macroglossia, tonsillar hypertrophy and tumors in the upper airway<sup>36</sup>.

The patient's cephalometric evaluation (Figure 1) provided information of various anatomical regions that maintain close correlation with obstructive sleep-disordered breathing. The results are listed in Table 1.



**Figure 1:** Patient's cephalometric lines, planes and angles evaluated in the present study.

**Table 1:** Summary of cephalometric measurements

Cephalometric variables	Baseline values	Normal
SNA (°)	82.7	82.00 ± 2.00
SNB (°)	75.2	80.00 ± 2.00
ANB (°)	7.5	2.00 ± 1.00
SN-MP (°)	39.6	32.00 ± 3.00
FMA (°)	27.8	25.00 ± 4.00
Ba-SN (°)	128.6	130.00 ± 5.00
PFH (mm)	85.7	88.00 ± 4.00
AFH (mm)	136.9	136.00 ± 6.00
PFH – AFH (%)	62.6	0.00
Ba- PNS (mm)	48.6	48.00 ± 4.00
SPAS (mm)	9.9	11.00 ± 3.00
PAS (mm)	6.9	11.00 ± 2.00
PNS-P (mm)	37.1	37.00 ± 3.00
SPL (mm)	11.7	11.00 ± 2.00
MPH (mm)	19.2	15.00 ± 3.00
H-C3 (mm)	35.9	40.00 ± 5.00
H-RGN (mm)	42.6	41.00 ± 8.00

PFH = posterior facial height; AFH= anterior facial height; PNS= posterior nasal spine; SPAS= superior posterior airway space; PAS= posterior airway space; PNS- P= posterior nasal spine to tip of palate; SPL= soft palate length; MPH= mandibular plane-hyoid distance; H-C3= Distance between the third cervical vertebrae and the hyoid bone; H-RGN = distance between the hyoid bone and retrognathic

When comparing to normal measurements<sup>36</sup>, the patient presented an increased ANB value (7.5°), indicating a possible mandibular retroposition. The SN-MP was also increased, and a correlation between posterior facial height - PFH and anterior facial height - AFH below 65% was observed, suggesting a clockwise facial growth. The posterior airway space - PAS decreased when compared to the normal pattern<sup>36</sup>. The soft palate length - SPL and the maximum palate thickness - TPS

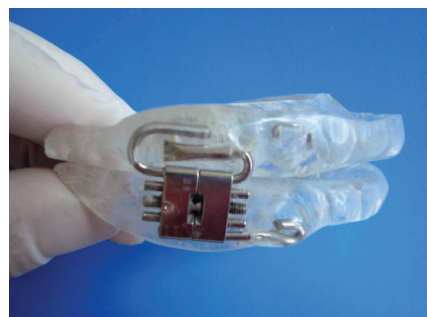exhibited normal patterns<sup>36</sup>. It was also identified that the distance from the hyoid bone to the mandibular plane - MPH was slightly increased, indicating a small displacement of the hyoid bone, despite the normal findings<sup>36</sup> in anteroposterior position (H-C3 and H-RGN) (Table 1).

It was found 81.66 mm for a standard of 72.50 ± 3.00 of Tongue-Length and 25.78 mm for a standard 24.00 + 3.00 of Tongue-Height, indicating that the patient has a greater lingual length when compared to the standard measurements<sup>37</sup>.

### 3.4 Oral appliances

Concerning the mechanism of action, both oral appliances were mandibular advancement devices used to modify the position of upper airway structures in order to enlarge the airway<sup>8</sup>.

- **PM Positioner™**<sup>29</sup>: The device has plates that fit over all upper and lower teeth. Expansion screws are located in the left and right mouth areas to allow maximum space for the tongue and favor the forward positioning of the jaw for maximum effectiveness. The clamps are placed internally to the plates for better retention of the device. Forty-four forward positions are available in increments of 0.25 mm, covering 11.0 mm range of anteroposterior movement<sup>29</sup> (Figure 2).

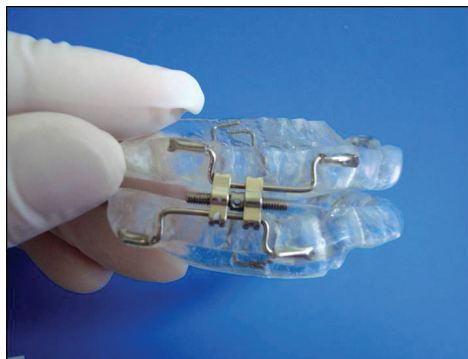

**Figure 2:** Mandibular advancement device: *PM Positioner™*.

- **Placa Lateroprotrusiva- PLP® Device:** This device was developed by one of the authors (Dr. Guimarães), and consists of two encapsulated acrylic plates retained by the two arcades through retaining clamps. The plates are latero-posteriorly joined together by accessories that enable lateral movements and progressive advancement of the mandible. These accessories are made of screw expanders that will receive barcode orientation drive.

The screws are available in increments of 0.25 mm, comprising a total of 11 mm in anteroposterior movement. The guide bars have a bayonet shape and their tips are held to the acrylic plates with the aid of telescopic tubes. These tubes allow the movement of laterality. The configuration of the bars follows this format so they can pull the plates in an effective manner, allowing the progressive advancement of the mandible.

The plates have acrylic tracks that allow progressive advancement and laterality movement of the jaw, which are realized in a stable, solid, and interference-free path. Although such tracks have the purpose of guiding the movement, they have no function in relation to existing orthopedic devices (Figure 3).



**Figure 3:** Mandibular advancement device: *Placa Lateroprotrusiva-PLP®*.

The patient’s treatment was based on the recommendations proposed by the American Academy of Sleep Medicine<sup>38</sup>. To obtain the maximum protrusion and bite registration for the oral appliance manufacture, the George Gauge device® was used. The maximum protrusion was of 12 mm, and the therapeutic protrusion was calculated at 70% (8.4 mm) of this measure. The PM Positioner™<sup>29</sup> device was the first choice for the patient’s treatment. The OA was made in maximum habitual intercuspation - MHI due to the patient’s history of joint pain while making use of OA.

The vertical height was 2mm, considering the patient facial type. After installing the device, the patient underwent four visits for protrusion adjustments, reaching the maximum of 6 mm of adjustment due to complaints of mild pain in the TMJ. The patient was then referred for overnight

polysomnography with the OA for therapeutic control. Despite the results showed no improvement in AHI, an improvement in oxygen saturation was observed (93.1%).

The PM Positioner™ device was used for 8 months. Nevertheless, the control polysomnography did not present satisfactory results, therefore after a two-weeks interval of wash-out<sup>39,40</sup> this device was substituted by an OA that enabled laterality – the PLP®. After installing this device, the patient underwent for four clinical visits, and the protrusion achieved was of 8 mm, and again, the patient was referred for an overnight polysomnography with the oral appliance. The patient underwent regular dental follow-up visits every six months as well as control polysomnographies, on November, 2007 and August, 2011 (Table 2).

**Table 2:** Polysomnography results in relation to time and type of oral appliance used.

Variables	Baseline	Oral appliance PMP™	Oral appliance PLP®	Oral appliance PLP®
Date (month/day/year)	09/06/2003	06/20/2004	11/11/2007	08/31/2011
AHI (/h)	16.2	16.4	8.9	5.6
AI (/h)	9.7	1	1.6	0.1
HI (/h)	6.5	15.4	7.3	5.4
Min Sa O <sub>2</sub> (%)	55	72	83.9	88
Sa O <sub>2</sub> (%), TST < 90%	99.5	7.3	48	1
Sleep efficiency (%)	81	95.9	78	89.3
Stage N3 (%)	7	0	5	4.7
REM sleep (%)	18	19.7	22	23.9
Arousal index (/h)	35.6	3	12	8.7
BMI (Kg/m <sup>2</sup> )	31.2	31.2	27.5	27.0

AHI= apnea-hipopnea index; AI = apnea index; HI= hypopnea index; SaO<sub>2</sub>= oxygen saturation by pulse oximetry; TST= Total sleep time (minutes); REM= rapid eyes movement; BMI=body mass index.

By the end of the study, the patient continued reporting improvements in the sleep quality, and was feeling more prepared for daily activities, with no daytime sleepiness. No pain in the masticatory muscles and TMJ was reported.

Both OAs were made with hard acrylic. Toothaches caused by devices made with hard acrylic are indicative of a defect in its construction, which can be eliminated by adjusting the plate in the corresponding area of the affected teeth<sup>26</sup>.

The need for successful management of treatments with OA in the long term has been stated in literature<sup>41</sup> The efficacy of the patient’s treatment from September 2003 to August 2011 revealed that the patient’s respiratory parameters were stable and controlled, as well as the subjective reports of restful

sleep and no drowsiness. The patient of the present study had moderate OSAS, and clinical characteristics favorable to the use of OA. The results are consistent, with evidence of improvement in subjective sleepiness and respiratory disturbance indexes presented by a Cochrane review<sup>41</sup>.

A study published in 2000 reported no adverse effects after two years of use of a monoblock<sup>37</sup>. However, some authors have mentioned that rigid OAs that do not allow movements of laterality may cause more TMJ dysfunction, leading to less compliance by patients<sup>26</sup>, which is consistent with the findings in the present case report.

During the treatment with the PM Positioner™, the patient complained of pain in TMJ and muscles, which limited the titration of the OA. Data from the first polysomnography showed significant improvement in oxygen saturation and apnea index, but not in the AHI. Therefore, after using the first OA for 8 months, the device was replaced by the PLP®, which allows lateral mandibular movements and provides greater comfort and less facial pain, enabling greater mandibular advancement.

Nocturnal oxygenation normalization depends significantly on the body weight and the severity of desaturation before treatment<sup>42</sup>. Moreover, the mandibular advancement results in dose-dependent reduction of closing pressure of the pharynx<sup>43,44</sup>. Successful nocturnal oxygenation improvement seems to be achieved when the OA reduces the pharynx closing pressure below atmospheric pressure, and each 2 mm of mandibular advancement coincides with approximately 20% improvement in the quantity and severity of nocturnal desaturation<sup>42</sup>. The present data are in compliance with the previous studies, once greater normalization of oxygenation was found with major advances in the patient protrusion.

Although some studies have reported that mouth vertical opening should be the lowest possible, there is still no polysomnographic study establishing the optimal vertical opening between the incisors, but the most adopted opening measure is of 2 mm<sup>26</sup>.

It is worth mentioning that possible collateral effects related to the use of oral appliances were not investigated. Therefore, the lack of cephalometric analysis and further evaluations for controlling the patient before and after the treatment with the OAs are limitations of the present study.

A recent review on the effectiveness of different devices found that when monoblock devices are compared with devices made by two pieces, no significant differences were observed regarding the reductions in AHI<sup>20</sup>. Despite the PM Positioner™ is a two-piece appliance, it does not allow lateral movements, and in this case this characteristic resulted in limiting the degree of mandibular advancement due to joint/ muscle pain, while devices such as PLP® allowing lateral movements provide greater comfort and better results concerning the reduction in AHI as well as improvements in oxygenation.

## 4 Conclusion

The choice related to the type of OA for OSAS treatment can influence the treatment effectiveness. In the present study, the OA that enabled lateral movements was more effective, once less discomfort and greater possibility of mandibular advancement was observed.

## References

1. Sleep-related breathing disorders in adults: recommendations for syndrome definition and measurement techniques in clinical research. The Report of an American Academy of Sleep Medicine Task Force. *Sleep* 1999;22(5):667-89.
2. Flemons WW. Clinical practice. Obstructive sleep apnea. *N Engl J Med* 2002;347(7):498-504.
3. Parish JM, Adam T, Facchiano L. Relationship of metabolic syndrome and obstructive sleep apnea. *J Clin Sleep Med* 2007;3(5):467-72.
4. Young T, Palta M, Dempsey J, Skatrud J, Weber S, Badr S. The occurrence of sleep-disordered breathing among middle-aged adults. *N Engl J Med* 1993;328(17):1230-5.
5. Tufik S, Santos-Silva R, Taddei JA, Bittencourt LR. Obstructive sleep apnea syndrome in the Sao Paulo Epidemiologic Sleep Study. *Sleep Med* 2010;11(5):441-6.
6. Barbe, PJ, Munoz A, Findley L, Anto JM, Agustí AG. Automobile accidents in patients with sleep apnea syndrome. An epidemiological and mechanistic study. *Am J Respir Crit Care Med* 1998;158(1):18-22.
7. Lavigne GJ, Cistulli PA, Smith MT. *Sleep Medicine for Dentists: a practical overview*. Quintessence, Canada; 2009p 53-59.
8. Somers VK, White DP, Amin R, Abraham WT, Costa F, Culebras A, et al. Sleep apnea and cardiovascular disease: an American Heart Association/American College of Cardiology Foundation Scientific Statement from the American Heart Association Council for High Blood Pressure Research Professional Education Committee, Council on Clinical Cardiology, Stroke Council, and Council on Cardiovascular Nursing. In collaboration with the National Heart, Lung, and Blood Institute National Center on Sleep Disorders Research (National Institutes of Health). *Circulation* 2008;118(10):1080-111.
9. Thorpy M J. Classification of Sleep Disorders. *Neurotherapeutics* 2012; 9(4):687-701.
10. Bittencourt L. Diagnóstico e tratamento da Síndrome da Apnéia Obstrutiva do Sono (SAOS)-Guia Prático. 1 ed. São Paulo: Médica Paulista, 2008.
11. Schmidt-Nowara W, Lowe A, Wiegand L, Cartwright R, Perez-Guerra F, Menn S. Oral appliances for the treatment of snoring and obstructive sleep apnea: a review. *Sleep* 1995;18(6):501-10.
12. Sari E, Menillo S. Comparison of titratable oral appliance and mandibular advancement splint in the treatment of patients with obstructive sleep apnea. *ISRN Dent* 2011;2011:581-692.
13. Gale DJ, Sawyer RH, Woodcock A, Stone P, Thompson R, O'Brien K. Do oral appliances enlarge the airway in patients with obstructive sleep apnoea? A prospective computerized tomographic study. *Eur J Orthod* 2000;22(2):159-68.
14. Ellis SG, Craik NW, Deans RF, Hanning CD. Dental appliances for snoring and obstructive sleep apnoea: construction aspects for general dental practitioners. *Dent Update* 2003;30(1):16-22.

15. Ferguson KA, Cartwright R, Rogers R, Schmidt-Nowara W. Oral appliances for snoring and obstructive sleep apnea: a review. *Sleep* 2006;29(2):244-62.
16. Epstein LJ, Kristo D, Strollo PJ Jr., Friedman N, Malhotra A, Patil SP, et al. Clinical guideline for the evaluation, management and long-term care of obstructive sleep apnea in adults. *J Clin Sleep Med* 2009;5(3):263-76.
17. Macías-Escalada E, Carlos-Villafranca F, Cobo-Plana J, Díaz-Esnal B. Aparatología intraoral en el tratamiento de la apnea-hipopnea obstructiva del sueño (SAHOS). *RCOE* 2002;7(4):391-402.
18. Cartwright RD, Samelson CF. The effects of a nonsurgical treatment for obstructive sleep apnea. The tongue-retaining device. *JAMA* 1982;248(6):705-9.
19. Barthlen GM, Brown LK, Wiland MR, Sadeh JS, Patwari J, Zimmerman M. Comparison of three oral appliances for treatment of severe obstructive sleep apnea syndrome. *Sleep Med* 2000;1(4):299-305.
20. Ahrens A, McGrath C, Hagg U. A systematic review of the efficacy of oral appliance design in the management of obstructive sleep apnoea. *Eur J Orthod* 2011;33(3):318-24.
21. Eckhart JE. Comparisons of oral devices for snoring. *J Calif Dent Assoc* 1998;26(8):611-23.
22. Meurice JC, Marc I, Carrier G, Series F. Effects of mouth opening on upper airway collapsibility in normal sleeping subjects. *Am J Respir Crit Care Med* 1996;153(1):255-9.
23. Shoaf SC. Sleep disorders and oral appliances: what every orthodontist should know. *J Clin Orthod* 2006;40(12):719-22.
24. Sharma SK, Katoch VM, Mohan A, Kadhiravan T, Elavarasi A, Ragesh R, et al. Consensus & Evidence-based INOSA Guidelines 2014 (First edition). *Indian J Med Res* 2014;140(3):451-68.
25. Chan AS, Lee RW, Cistulli PA. Dental appliance treatment for obstructive sleep apnea. *Chest* 2007;132(2):693-9.
26. George PT. Selecting sleep-disordered-breathing appliances. Biomechanical considerations. *J Am Dent Assoc* 2001;132(3):339-47.
27. Woodson BT. Non-pressure therapies for obstructive sleep apnea: surgery and oral appliances. *Respir Care* 2010;55(10):1314-21.
28. Sutherland K, Vanderveken OM, Tsuda H, Marklund M, Gagnadoux F, Kushida CA, et al. Oral appliance treatment for obstructive sleep apnea: an update. *J Clin Sleep Med* 2014;10(2):215-27.
29. Parker J. A prospective study evaluating the effectiveness of a mandibular repositioning appliance (PM Positioner) for the treatment of moderate obstructive sleep apnea. *Sleep* 1999;22(1):230-1.
30. Johns MW. A new method for measuring daytime sleepiness: the Epworth sleepiness scale. *Sleep* 1991;14(6):540-5.
31. Garrow JS, Webster J. Quetelet's index (W/H<sup>2</sup>) as a measure of fatness. *Int J Obes* 1985;9(2):147-53.
32. Reis SAB, Abrão J, Capelozza Filho I, Claro CAA. Análise facial numérica do perfil de brasileiros Padrão I. *Dental Press Ortodon Ortop Facial* 2006;11(6):24-34.
33. Pereira CB, Mundstock CA, Berthold TB. Introdução à Cefalometria Radiográfica. São Paulo: Pancast; 1998.
34. Momjian A, Courvoisier D, Kiliaridis S, Scolozzi P. Reliability of computational measurement of the condyles on digital panoramic radiographs. *Dentomaxillofac Radiol* 2011;40(7):444-50.
35. Marques CG, Maniglia JV. Estudo cefalométrico de indivíduos com Síndrome da Apnéia Obstrutiva do Sono: revisão da literatura. *Arq Ciênc Saúde* 2005; 12(4):206-12.
36. Dal Fabbro C, Júnior CMC, Tufik SA. A Odontologia na Medicina do Sono. 1ª Ed São Paulo: Dental Press; 2010.p.145-346.
37. Bondemark L, Lindman R. Craniomandibular status and function in patients with habitual snoring and obstructive sleep apnoea after nocturnal treatment with a mandibular advancement splint: a 2-year follow-up. *Eur J Orthod* 2000;22(1):53-60.
38. Kushida CA, Morgenthaler TI, Littner MR, Alessi CA, Bailey D, Coleman J Junior, et al. Practice parameters for the treatment of snoring and Obstructive Sleep Apnea with oral appliances: an update for 2005. *Sleep* 2006;29(2):240-3.
39. Zhou J, Liu YH. A randomised titrated crossover study comparing two oral appliances in the treatment for mild to moderate obstructive sleep apnoea/hypopnoea syndrome. *J Oral Rehabil* 2012;39(12):914-22.
40. White DP, Shafazand S. Mandibular advancement device vs. CPAP in the treatment of obstructive sleep apnea: are they equally effective in Short term health outcomes? *J Clin Sleep Med* 2013;9(9):971-2.
41. Lim J, Lasserson TJ, Fleetham J, Wright J. Oral appliances for obstructive sleep apnoea. *Cochrane Database Syst Rev* 2006;(1):CD004435.
42. Kato J, Isono S, Tanaka A, Watanabe T, Araki D, Tanzawa H, et al. Dose-dependent effects of mandibular advancement on pharyngeal mechanics and nocturnal oxygenation in patients with sleep-disordered breathing. *Chest* 2000;117(4):1065-72.
43. Vroegop AV, Vanderveken OM, Van de Heyning PH, Braem MJ. Effects of vertical opening on pharyngeal dimensions in patients with obstructive sleep apnoea. *Sleep Med* 2012;13(3):314-6.
44. Chan AS, Sutherland K, Schwab RJ, Zeng B, Petocz P, Lee RW, Darendeliler MA, Cistulli PA. The effect of mandibular advancement on upper airway structure in obstructive sleep apnoea. *Thorax* 2010;65(8):726-32.