

The Radiographic Management for Surgical Planning and Implant Placement: a Case of Atypical Antral Artery Position

Avaliação Radiográfica no Planejamento Cirúrgico para Instalação de Implante Dentário: um Caso de Posição Atípica da Artéria Antral

Júlio César Schroder^{a*}; Ana Paula Tulio Manfron^a; Alessandra S. Ditzel^a; Aaron Trujillo^a; Angela Deliga Schroder^a; Guilherme Strujak^a; Fernando H. Westphalen^b

^aPontifícia Universidade Católica of Paraná, Post-Graduation Program. PR, Brazil.

^bUniversity of Parana, Department of Radiology. PR, Brazil.

*E-mail: jcschroder@hotmail.com

Recebido em: 18/10/2017; Aceito em: 17/01/2018

Abstract

It is very important the knowledge of the maxillary sinus blood supply, in particular of the lateral maxillary wall, due to the possibility of accidental rupture of a vessel during the sinus floor augmentation. A case report is described of a 65-year-old female, who reported a postoperative complication after a sinus augmentation that she had had 3 years before. After radiographic evaluation, it was observed the presence of antral artery in atypical position. The identification of this anatomical structure is very important, by preoperative radiographic examination, avoiding possible bleeding complications, during and after the surgical procedures.

keywords: Cone-Beam Computed Tomography. Maxillary Sinus. Surgical Procedures, Operative.

Resumo

O conhecimento do suprimento sanguíneo do seio maxilar, em particular da parede lateral, é de considerável importância devido à possibilidade de rompimento acidental de uma artéria durante os procedimentos de elevação do assoalho do seio maxilar. Paciente do sexo feminino, 65 anos de idade, com histórico de complicação pós-operatória, após procedimento de elevação do seio maxilar realizado há três anos. Após avaliação tomográfica, foi observada a presença da artéria antral em posição atípica. Identificar e reconhecer essa estrutura anatômica pelo exame radiográfico pré-operatório, evita possíveis complicações hemorrágicas, durante e após o procedimento cirúrgico.

Palavras-chave: Tomografia Computadorizada de Feixe Cônico. Seio Maxilar. Procedimentos Cirúrgicos Operatórios.

1 Introduction

The presence of severe bone atrophy becomes a great challenge in rehabilitation with dental implants¹. In cases of the posterior maxilla region, where alveolar bone resorption and maxillary sinus cavity pneumatization often compromises dental implant therapy, the maxillary sinus floor elevation technique with lateral approach has been used, for a long time, with high success predictability²⁻⁴.

The maxillary sinus blood supply is derived from three branches of the maxillary artery: the infraorbital artery, the descending palatine artery and the posterior superior alveolar artery. Usually the posterior superior alveolar artery and the infraorbital artery form anastomoses, thus, the most important is called alveolar antral artery. The artery passes through the area where the bony window is most frequently opened during sinus floor elevation⁵⁻⁷. Studies demonstrated the overall mean size of the diameter of the superior alveolar artery is 1.09 mm, means ranging from 0.8 mm to 1.59 mm⁸⁻¹⁵. In order to prevent bleeding complications and maxillary bone necrosis during surgical procedures, involving this region, it is very important the knowledge on the blood supply and the sinus cavity vascularization, in particular of the lateral maxillary wall, due to an accidental rupture of a vessel during the osteotomy. Although some case series have described lower incidences,

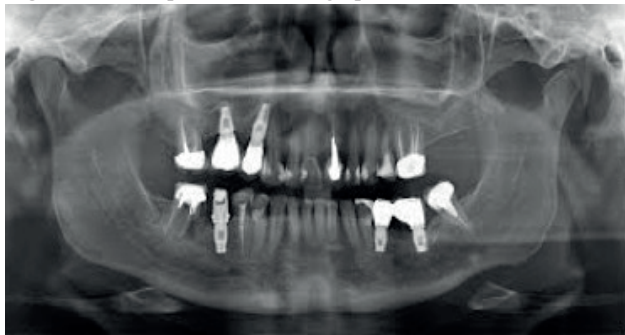studies reported up to 20% of bleeding events¹⁶⁻¹⁸.

Knowledge on the anatomical course of the posterior alveolar artery and its anastomoses is really important for a surgical procedure. Two-dimensional radiographs (panoramic radiograph and periapical) are limited in the observation of these anatomical structures. Due to this fact, the cone beam computer tomography (CBCT) provides a better observation, especially the distribution and the clinically relevant distance^{7,10,18}. The purpose of this clinical case report was to emphasize the knowledge and radiographic interpretation of the presence of alveolar antral artery during sinus elevation and to discuss the clinical effects of these findings in oral rehabilitation.

2 Case Report

A 65-year-old female was addressed to private clinical, seeking implant rehabilitation in the region of first upper molar on the left side (Figure 1). At the previous pre-operative evaluation, the patient reported a postoperative complication, like bleeding, swelling and pain after a sinus augmentation that she had had 3 years before. Regarding the radiographic history, she reported that in the first intervention, she had performed only a panoramic radiography.

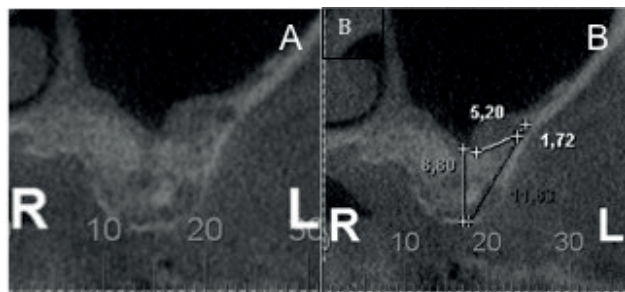
Figure 1- Initial panoramic radiograph



Source: The authors.

For a new intervention after clinical examination, for a better and safe surgical planning, a CBCT was requested and maxillary sinus floor elevation was indicated combined with grafting. Decision was taken for a one-stage technique with sinus elevation and simultaneous implant placement, on the left maxillary sinus. On a sagittal and cross-section CBCT images an alveolar antral artery was observed with diameter, measured in the CBCT, of about 1.72 mm, distance to alveolar antral artery to sinus floor 5.2 mm and distance of alveolar antral to alveolar crest of 11.63 mm, in the area planned for sinus elevation (Figure 2A e 2B).

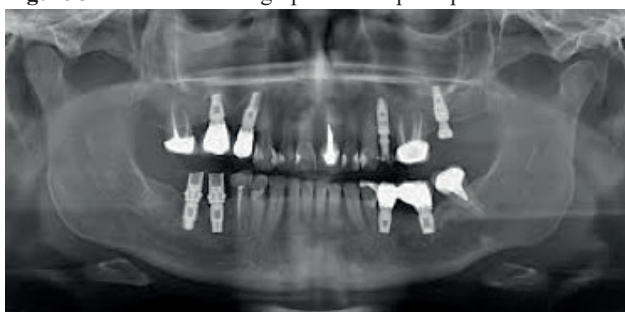Figure 2 - (A) Sagittal cross-section shows the antral artery. **(B)** Measurements in the area of sinus elevation: diameter 1.72 mm; distance between antral artery to sinus floor 5.2 mm and distance between antral to alveolar crest 11.63 mm.



Source: The authors.

Due to the presence of such a delicate and wide (in diameter) vascular structure in the area subjected to the surgical procedure, a modified sinus lift technique was proposed avoiding alveolar antral artery and in a second time the implant placement, as shown in the panoramic radiograph (Figure 3).

Figure 3. Panoramic radiograph after implant placement.



Source: The authors.

2.1 Discussion

Damage of the alveolar antral artery during sinus augmentation with lateral approach can cause intense bleeding, hindering vision and may lead to perforation of the Schneiderian membrane in surgical procedure¹⁰. Sinus elevation procedure was first published by Boyne and James¹⁹ and lateral window techniques was reported by Tatum²⁰. The area anatomy should be carefully examined before surgical interventions, principally in lateral window techniques²¹. The blood supply in this region is composed by the posterior superior alveolar artery and the infraorbital artery²². Anastomosis branches are located between the posterior superior alveolar artery and the infraorbital artery, both in the intra- and extra-osseous context²³.

Rosano et al.¹² observed that in 100% of thirty dry maxillary sinus cases, there was an intraosseous anastomosis between posterior superior alveolar artery and the infraorbital artery. This anastomosis is also known as alveolar antral artery. The alveolar antral artery appears an intraosseous position ranging mean 64.3% to 71.4% of the cases and the intrasinus position ranging mean 14.3% to 52.8% of the cases^{7,10,13,25,26}. This case reported an intrasinus position of the artery. The intraosseous branch usually describes a S-straight or U-shaped course, forming a concave arch whose closest point to the osseous crest is located near the first molar region. This branch supplies the Schneiderian membrane, periosteum, and the lateral sinus wall.^{11,12,14,16,27}

The distance reported herein between the alveolar antral artery and sinus floor was 5.2 mm. and the distance between the alveolar antral artery and the alveolar crest reported in this case is consistent with the study²⁵ that shows that in edentulous patients the distance is shorter when compared with dentate patients. In this case the diameter was 1.72 mm, the literature demonstrated in more than 10% of cases, there is a risk of bleeding in artery with a diameter of 0.5 mm and, with the diameter more than 0.5 mm (1 to 2 mm), the probability of a high risk of hemorrhage is about 57%^{7,10,11,25}. In addition, considering the minimum height and the maximum external diameter of the antral artery, a precaution should be taken for the possibility of severe bleeding during or after osteotomy and modified techniques approaches¹. Panoramic radiographs are limited in the observation of these blood vessels. Detection of this artery is possible using a CBCT or CT scan that offers more precise and reliable linear measurements for imaging and maxillofacial structures reconstruction¹⁰. A preoperative CBCT scan can be used as a better diagnostic tool to reduce surgical complications in suspected cases as well as conditions that may involve this artery^{23,28}. Therefore, the use of CBCT is recommended as a routine procedure prior to sinus floor elevation²⁶.

According to this case report and the literature review deep knowledge on the anatomy of this region is necessary before the surgical interventions for a safety surgery and for

a better integration of the grafting and implant. Due to this fact, the most importance of this case report is highlight the presence of these anatomic findings and could represent an alert to the general dentist in cases of surgery procedures.

4 Conclusions

The presence of alveolar antral artery and more precise information about the anatomical structure, can be revealed in cross sectional CBCT images. The identification of this anatomical structure is very important, through preoperative radiographic examination, avoiding possible bleeding complications, during and after the surgical procedures.

References

- Isaksson S, Alberius P. Maxillary alveolar ridge augmentation with onlay bone-grafts and immediate endosseous implants. *J Craniomaxillofac Surg* 1992;20:2-7.
- Jemt T, Lekholm U. Implant treatment in edentulous maxillae: a 5-year follow-up report on patients with different degrees of jaw resorption. *Int J Oral Maxillofac Implants* 1995;10:303-11.
- Becktor JP, Hallström H, Isaksson S, Sennerby L. The use of particulate bone grafts from the mandible for maxillary sinus floor augmentation before placement of surface-modified implants: results from bone grafting to delivery of the final fixed prosthesis. *J Oral Maxillofac Surg* 2008;66:780-86.
- Gerressen M, Riediger D, Hilgers RD, Hölzle F, Noroozi N, Ghassemi A. The volume behavior of autogenous iliac bone grafts after sinus floor elevation: a clinical pilot study. *J Oral Implantol* 2015;41:276-83. doi: 10.1563/AAID-JOI-D-13-00246.
- Flanagan D. Arterial supply of maxillary sinus and potential for bleeding complication during lateral approach sinus elevation. *Implant Dent* 2005;14:336-38.
- Van den Bergh JP, Ten Bruggenkate CM, Disch FJ, Tuinzing DB. Anatomical aspects of sinus oor elevations. *Clin Oral Implants Res* 2000;11:256-65.
- Kang SJ, Shin SI, Herr Y, Kwon YH, Kim GT, Chung JH. Anatomical structures in the maxillary sinus related to lateral sinus elevation: a cone beam computed tomographic analysis. *Clin. Oral Implants Res* 2013;24:75-81. doi: 10.1111/j.1600-0501.2011.02378.x.
- Watanabe T, Shiota M, Gao S, Imakita C, Tachikawa N, Kasugai S. Verification of posterior superior alveolar artery distribution in lateral wall of maxillary sinus by location and defect pattern. *Quintessence Int* 2014;45:673-8. doi: 10.3290/j.qi.a32239.
- Kim JH, Ryu JS, Kim KD, Hwang SH, Moon HS. A radiographic study of the posterior superior alveolar artery. *Implant Dent* 2011;20:306-10.
- Ella B, Sédarat C, Noble RDC, Normand E, Lauverjat Y, Siberchicot F. et al. Vascular connections of the lateral wall of the sinus: surgical effect in sinus augmentation. *Int J Oral Maxillofac Implants* 2008;23:1047-52.
- Solar P, Geyerhofer U, Traxler H, Windisch A, Ulm C, Watzek G. Blood supply to the maxillary sinus relevant to sinus floor elevation procedures. *Clin Oral Implants Res* 1999;10:34-4.
- Rosano G. Maxillary sinus vascularization: a cadaveric study. *J Craniofac Surg* 2009;20:940-3.
- Güncü GN, Yildirim YD, Wang HL, Tözüm TF. Location of posterior superior alveolar artery and evaluation of maxillary sinus anatomy with computerized tomography: a clinical study. *Clin Oral Implants Res* 2011;22:1164-67.
- Hur MS, Kim JK, Hu KS, Bae HE, Park HS, Kim HJ. Clinical implications of the topography and distribution of the posterior superior alveolar artery. *J Craniofac Surg* 2009;20:551-4.
- Mardinger O, Abba M, Hirshberg A, Schwartz-Arad D. Prevalence, diameter and course of the maxillary intraosseous vascular canal with relation to sinus augmentation procedure: a radiographic study. *Int J Oral Maxillofac Surg* 2007;36:735-8.
- Zijderveld SA, van den Bergh JP, Schulten EA, ten Bruggenkate CM. Anatomical and surgical findings and complications in 100 consecutive maxillary sinus floor elevation procedures. *J Oral Maxillofac Surg* 2008;66:1426-38.
- Apostolakis D, Bissoon AK. Radiographic evaluation of the superior alveolar canal: Measurements of its diameter and of its position in relation to the maxillary sinus oor: a cone beam computerized tomography study. *Clin Oral Implants Res* 2014;25:553-9. doi: 10.1111/clr.12119.
- Franciosi F. Arteria alveolo-antrale di grosso calibro. Caso clinico. *Dent Cadmos* 2013;81:532-7.
- Boyne PJ, James RA. Grafting of the maxillary sinus floor with autogenous marrow and bone. *J Oral Surg* 1980;38:613-6.
- Tatum OH. Maxillary and sinus implant reconstruction. *Dent Clin North Am* 1986;30:207-29.
- Regev E, Smith RA, Perrot DH, Pogrel MA. Maxillary sinus complications related to endosseous implants 1995;10:451-61.
- Rysz M, Ciszek B, Rogowska M, Krajewski R. Arteries of the anterior wall of the maxilla in sinus lift surgery. *Int J Oral Maxillofac Surg* 2014;43:1127-30.
- Rahpeyma A, Khajehahmadi S. Alveolar antral artery: review of surgical techniques involving this anatomic structure. *Iran J Otorhinolaryngol* 2014;26:73-8.
- Elian N, Wallace S, Cho SC, Jalbout ZN, Froum S. Distribution of the maxillary artery as it relates to sinus floor augmentation. *Int J Oral Maxillofac Implants* 2005;20:784-7.
- Ilgüy D., Ilgüy M., Dolekoglu S., Fisekcioglu E.. Evaluation of the posterior superior alveolar artery and the maxillary sinus with CBCT. *Braz Oral Res* 2013;27:431-7.
- Jung JI, Yim JH, Kwon YD, Al-Nawas B, Kim GT, Choi BJ, Lee DW. A radiographic study of the position and prevalence of the maxillary arterial endosseous anastomosis using cone beam computed tomography. *Int J Oral Maxillofac Implants* 2011;26:1273-8.
- Anamali S, Avila-Ortiz G, Elangovan S, Qian F, Ruprecht A, Finkelstein M. et al. Prevalence of the posterior superior alveolar canal in cone beam computed tomography scans. *Clin Oral Implants Res* 2013. doi.org/10.1111/clr.12318.
- Shahidi S, Zamiri B, Momeni Danaei S, Salehi S, Hamedani S. Evaluation of anatomic variations in maxillary sinus with the aid of Cone Beam Computed Tomography (CBCT) in a Population in South of Iran. *J Dent (Shiraz)* 2016;17:7-15.