

## Therapeutic Approach in Large Periapical Cyst: Clinical Case Report

### Abordagem Terapêutica em Cisto Periapical de Grande Proporção: Relato de Caso Clínico

Daniele Dutra de Almeida<sup>a</sup>; Igor Felipe da Silva<sup>a</sup>; Caroline Wichnieski<sup>a</sup>; Ana Paula Tulio Manfron<sup>\*a</sup>; Maria Luiza Prosdócimo<sup>a</sup>

<sup>a</sup>Faculdade Herrero. RJ, Brasil.

\*E-mail: [tulio.ana@gmail.com](mailto:tulio.ana@gmail.com)

---

#### Abstract

Periapical cysts of endodontic origin originate from an infection that affects the apical region, causing pulpal necrosis that stimulates an inflammatory response. Among many pathologies found on radiographs, one of them is the root cyst, considered to be a lesion frequently found in the maxilla and mandible, associated with the apex of a tooth with pulp necrosis. They present slow growth and are discovered in routine examinations because they are asymptomatic. Due to the chronic aggression, the lesion does not present painful symptoms in most cases, and grows slowly, thus being able to reach large extensions, with the presence of swelling and sensitivity, as well as slight mobility in the affected tooth and adjacent ones. The objective of this study was to report a clinical case of swelling in the anterior region of the mandible, which was diagnosed as a periapical cyst, in this way the treatments performed and the final result after 18 months of follow-up will be reported. However, to achieve good results during periapical cyst treatment, it is necessary to make a correct diagnosis, followed by adequate planning, always performing clinical and radiographic follow-up, in addition to the patient's cooperation, so that good results can be achieved during the treatment. It can be observed that a well-performed endodontic treatment, associated with a elaborated surgical technique, in addition to anatomopathological evidence and radiographic follow-up, make the therapeutic success to be obtained in cases of large periapical cysts.

**Keywords:** Radicular Cyst. Root Canal Therapy. Surgery, Oral.

#### Resumo

*Os cistos periapicais de origem endodôntica, originam-se a partir de uma infecção que acomete em região apical, ocasionando uma necrose pulpar que estimula uma resposta inflamatória. Das várias patologias encontradas radiograficamente, o cisto radicular tem sido o mais frequente encontrado, tanto em maxila, quanto em mandíbula, associado ao ápice de um dente com necrose pulpar. Apresentam crescimento lento e são descobertos nos exames de rotina, por serem assintomáticos. Devido a agressão crônica, a lesão não apresenta sintomatologia dolorosa, na maioria dos casos, tendo seu crescimento lento, desta maneira podendo atingir grandes extensões, com presença de tumefação e sensibilidade, além de leve mobilidade no dente acometido e nos adjacentes. O objetivo deste estudo foi relatar um caso clínico de tumefação na região anterior de mandíbula, o qual foi diagnosticado como cisto periapical, desta forma serão relatados os tratamentos realizados e o resultado final após 18 meses de acompanhamento. Contudo, para que sejam alcançados bons resultados durante o tratamento do cisto periapical é necessário realizar um correto diagnóstico, seguido por um planejamento adequado, realizando sempre o acompanhamento clínico e radiográfico, além da colaboração do paciente, para que possam ser atingidos bons resultados durante o tratamento. Pode-se observar que um tratamento endodôntico bem realizado, associado à uma técnica cirúrgica bem elaborada, além de comprovação anatomo-patológica e acompanhamento radiográfico, fazem com que o sucesso terapêutico seja obtido para os casos de cistos periapicais de grande proporção.*

**Palavras-chave:** Cisto Radicular. Tratamento do Canal Radicular. Cirurgia Bucal.

---

#### 1 Introduction

Periapical cysts or endodontic origin originate from an infection that affects the apical region, causing pulpal necrosis that stimulates an inflammatory response<sup>1,2</sup>. This periapical lesion is characterized by a capsule of fibrous connective tissue resulting from a pathological cavity coated by epithelium, containing lumen and epithelial remains of Mallassez<sup>1-3</sup> and can be found inside the maxilla and jaw, from a granuloma, and developing for a cyst<sup>1</sup>.

Due to the chronic aggression, the lesion does not present painful symptoms in most cases, and grows slowly, thus being able to reach large extensions, with the presence

of swelling and sensitivity, as well as slight mobility in the affected tooth and adjacent ones.

The most affected age group is adults between the third and the sixth decade of life<sup>2</sup>. They present in radiographic examinations a unilocular, radiolucidal, oval or rounded image, with well-defined limits surrounding the apex of the tooth involved, loss of the hard blade around the root of the tooth with necrosis can also be observed 3-7. A differential diagnosis is essential, due to the fact that other lesions present clinical and radiographic similarities with the root or periapical cyst, some examples are: unicistic ameloblastoma, odontogenic keratocyst and simple bone cyst<sup>8,9</sup>.

Treatment options may vary between endodontic and surgical treatment<sup>9</sup>. It is usually initiated with endodontic treatment, performing disinfection of root canals of the tooth involved<sup>9</sup>. In cases of lesions with large extensions, marsupialization (surgical maneuver on the cyst wall for cystic decompression) and cystic enucleation (performed a surgical procedure of total lesion removal)<sup>10</sup>.

Thus, it is essential to demonstrate the importance of a more conservative therapeutic approach, aiming the maintenance of teeth and bone, through techniques consolidated in literature, maintaining a therapeutic quality, in addition to reducing time and cost of treatment to the patient.

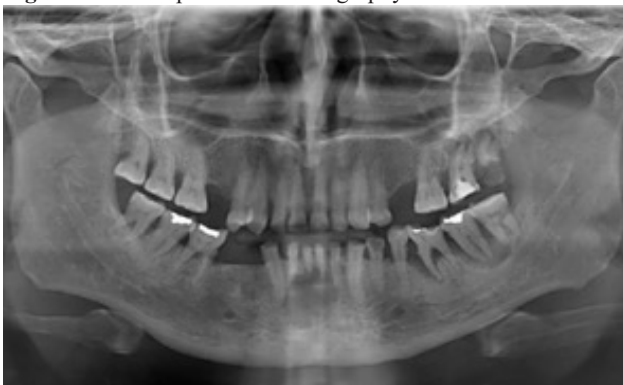Before the facts above mentioned, the objective of this study was to report a clinical case of swelling in the anterior region of the mandible, which was diagnosed as a periapical cyst, and to demonstrate the treatments performed and the final result after 18 months of follow-up will be reported.

## 2 Case Report

This case report was evaluated by the Research Ethics Committee involving Human Beings of the Faculty Herrero Curitiba-PR, and approved under number 5.364.478.

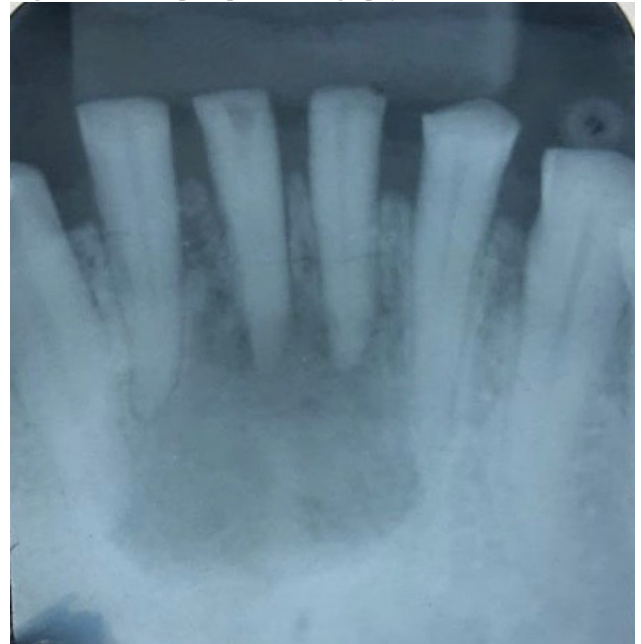Female patient, 50, attended the Dental Clinic of the Herrero College, reporting as main complaint: “To have short teeth”. After clinical examination and radiographic evaluation with panoramic radiography (Figure 1 and 2), radiolucent circumferential image was observed wrapped by radiopaque halo in the anterior mandibular region, near the apices of the anterior inferior incisors. In the clinical examination, necrosis with pulpal exposure of element 41, necrosis of 31 and presence of severe generalized dental wear was observed. At the inspection examination (Figure 3) a tumefaction in the gingival mucous region was identified between the elements 32 to 42, with purulent discharge through the gingival sulcus. To better understand the location and extent of the lesion, a cone beam computed tomography (CFC) was requested (Figure 4).

**Figure 1 - Initial panoramic radiography**



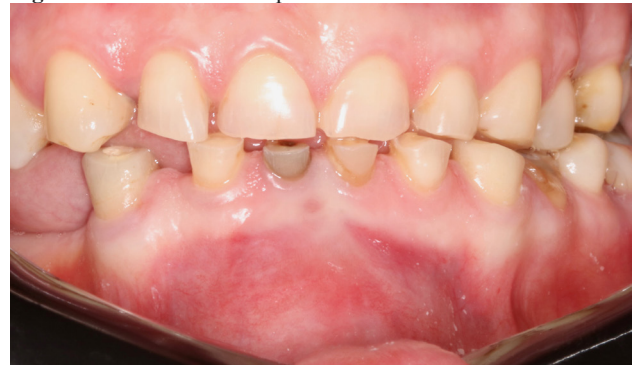Source: the authors.

**Figure 2 - Initial periapical radiography**



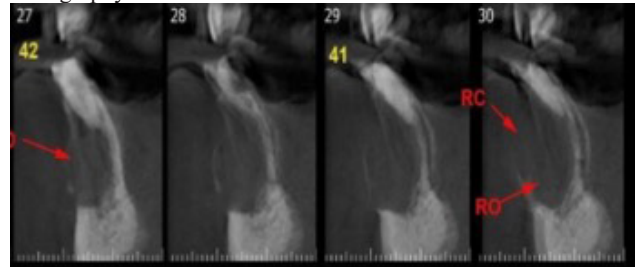
Source: the authors.

**Figure 3 - Initial clinical aspect of the lesion**



Source: the authors.

**Figure 4 - Parasagittal cutting of the mandible in computed tomography of the cone beam of the mandible**



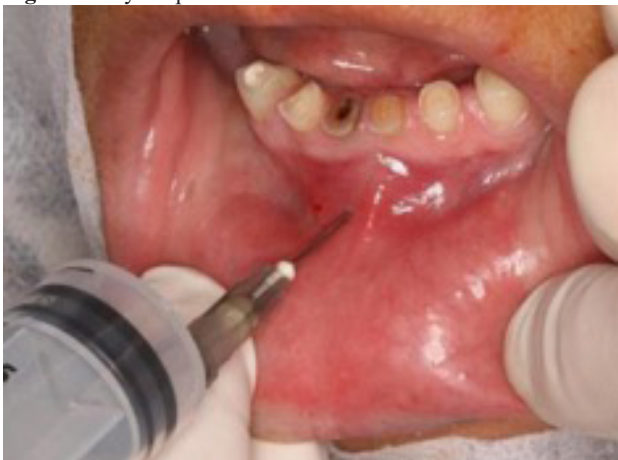Source: the authors.

For diagnostic confirmation, an incisional biopsy was performed in the area of tumefaction, but the initial result was inconclusive. Concomitant to a new surgical biopsy procedure, the endodontic approach (31,41,42 and 43) was initiated, with the application of intracanal calcium hydroxide medication for disinfection of the ducts, contributing to the immediate reduction of the cystic lesion size. After a month, all the teeth involved were filled.

During the waiting period with the intracanal medication, a new biopsy was performed as proposed in the treatment

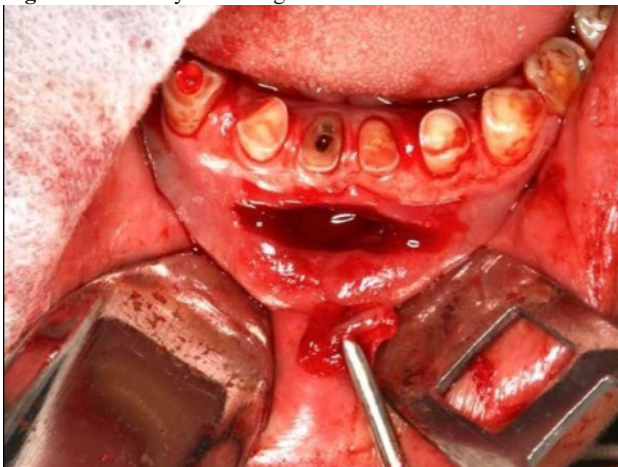
plan, to better understand and confirm the diagnosis. After the procedure of intraoral and extraoral antiseptics, the surgical procedure began. For better patient comfort, topical anesthetic was applied (Benzotop – DFL – Rio de Janeiro, Brazil), and then performed bilateral mental nerve anesthesia with short needle (Dencojet - DFL – Rio de Janeiro - Brazil), 3% Mepivacaine anesthetic solution with epinephrine vasoconstrictor 1:100,000 (Mepivale® AD – DLA Pharma – Catanduva, SP, Brazil). With a 20 ml luer syringe and a 25x7 mm needle (Descarpack – Ilhota, SC, Brazil), a puncture of the intracystic fluid was performed (Figure 5), which was thick, dark red, being a mixture of blood and purulent secretion. With a scalpel handle and carbon steel blade number 15C (Solidor® - São Paulo, SP, Brazil), a semilunar incision was performed on the cyst, allowing all the internal contents to be removed. Then with a Lucas octagonal curette (Golgran – São Caetano do Sul, SP, Brazil), total curettage was done of the cystic capsule (Figure 6), which was done in 2 parts. Finally, the suture was performed with simple continuous stitch with the thread of Nylon 4.0 (Shalon – São Luis de Montes Belos, GO, Brazil).

**Figure 5 - Cystic puncture**



Source: the authors

**Figure 6 - Total cyst curettage**




Source: the authors

After the surgical procedure, the patient received verbal

and written postoperative guidelines and recommendations. As post-surgical drug therapy the following medications were prescribed: Amoxicillin of 500mg hours, for 07 days + ibuprofen of 600mg of 06/06 hours, for 05 days paracetamol of 750mg of 08/08 6/6 hours, for 03 days, and also requested return after 7 days for suture removal and postoperative follow-up.

The collected fragment was stored in a 10% formalin solution for histopathological analysis, which the diagnosis of periapical cyst was obtained (Figure 7).

**Figure 7 - Results of histopathological examination**



UNIVERSIDADE FEDERAL DO RIO DE JANEIRO - FACULDADE DE ODONTOLOGIA  
DEPARTAMENTO DE PATOLOGIA E DIAGNÓSTICO ORAL

**LABORATÓRIO DE PATOLOGIA ORAL FO/UFRJ**

---

IDADE: 50	PROFISSIONAL SOLICITANTE: Dra. Maria Luiza P. Moreira	REGISTRO: 21-783AP
PROCEDÊNCIA: PART		REG. ORIGEM: 37417 CRO-RJ

---

EXAME REALIZADO: Anatomia Patológica	LOCAL: Mandíbula anterior
ENTRADA: 17/05/2021	SÁIDA: 24/05/2021 13:11:00

---

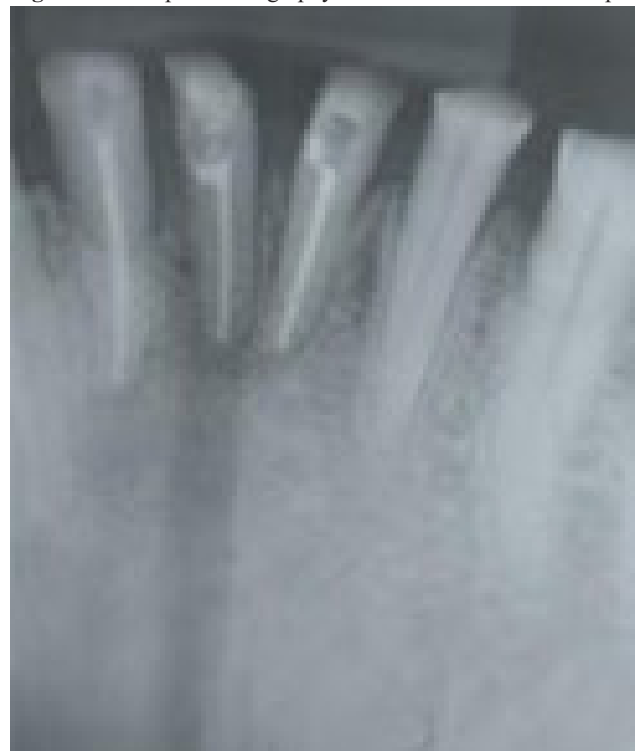**Macroscopia**      Dois fragmentos de tecido mole, recebidos em formol, de formato irregular, superfície irregular, consistência fibroelástica, coloração acastanhada e medindo 18 x 8 x 4 mm em conjunto.

**Conclusão**                      CISTO PERIAPICAL

Source: the authors.

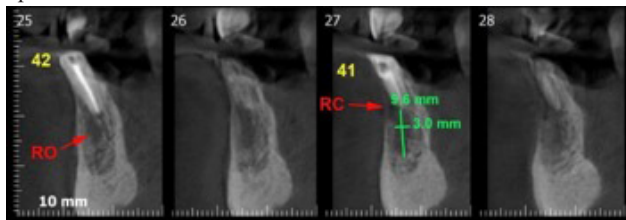
In a 18-month post-surgical follow-up, clinical and imaginative examination was performed (periapical radiography and CFC) (Figure 8 and 9), which found great bone regeneration, as presented in the following images:

**Figure 8 - Periapical radiography after 18 months of follow-up**



Source: the authors.

**Figure 9** - Tomographic radiography after 18 months of follow-up



Source: the authors.

## 2.1 Discussion

Periapical cyst is one of the most common among odontogenic cysts, and its etiology is derived from the pulp necrosis of one or more dental elements, which affects inflammation in the periapical region<sup>4,6</sup>. In the research carried out by Nanami *et al.*<sup>4</sup> the predominance of periapical cysts was pointed out in males, and more common in the fourth decade of life. According to Nobuhara *et al.*<sup>11</sup> a preliminary diagnosis can be made if the following characteristics are presented in the clinical and radiographic examination: periapical lesion involving one or more teeth with pulp necrosis, if the lesion is greater than 2 cm in diameter or cross-sectional area of 200mm<sup>2</sup>, the suction or drainage liquid has straw color and the fluid contains cholesterol crystals.

Matsumura *et al.*<sup>12</sup> reported that large-proportion lesions did not have as favorable results as small-sized lesions, on the other hand for Sjogren *et al.*<sup>14</sup> the size of the lesion does not interfere with the outcome of the treatment. In the study by Pereira *et al.*<sup>3</sup> the authors report that the factor that will interfere with a favorable prognosis is the thickness of the lesion capsule, because the cyst with the thicker capsule has a better ease of treatment than a thin capsule, according to the author, the level of difficulty is higher because it has a longer surgical time.

Different authors<sup>1,3,6,11,12</sup> point out the importance of an initial surgical treatment, prior to endodontic treatment. On the other hand, this sequence ends up being more invasive. However, the patient goes through fewer procedures, allowing for a faster and more favorable recovery of the case. For this, enucleation and/or marsupialization techniques are established, as well as tooth extraction. These techniques were not used as the first choice in the presented case, because it was shown to be very invasive initially for the patient's age, emphasizing the importance of a more delicate and less invasive treatment, seeking to occur less recurrence and satisfactory prognosis.

Oliveira *et al.*<sup>9</sup>, in his study, stated that endodontic therapy should be the first option for periapical cyst treatment, however, in case of failure, surgical therapy will be necessary. In the present report it can be observed after a few months the non-recurrence of cyst through endodontic treatment, proving the statements of the aforementioned authors. It can be analyzed that a less invasive treatment is of paramount importance, enabling a better treatment preserving.

Vasconcelos *et al.*<sup>14</sup> discuss in their study that periapical lesions result from the presence of bacterial endotoxins, as well as cytokines originated from immunoinflammatory processes in the root ducts and apical tissues. The success of treatment centralizes in the elimination of aggressor microorganisms. Thus, it was chosen for the reported case the elimination of aggressor agents through endodontic treatment of affected teeth, aiming a more conservative treatment, as the authors have pointed out. If the tooth can be maintained, endodontic therapy should be performed and if the radio transparency does not regress or disappear, the lesion can often be successfully treated by endodontic retreatment.

For the present case report it was chosen to perform the surgical technique of cystic enucleation, and to prove diagnosis, the piece was sent for histopathological analysis, and the diagnostic hypothesis of periapical cyst was proven. This procedure was performed after endodontic treatment. However, the literature shows that surgical treatment has its limitations, which can generate irreversible disorders for the patient, such as paresthesia, devitalization of the adjacent tooth, and loss of bone support<sup>5,8-10</sup>.

As Rezende *et al.*<sup>6</sup> cysts of inflammatory origin did not recite after proper treatment, and occasionally fibrous scars may occur instead of bone neoformation. In relation to the clinical case, the patient was in follow-up in the 18 postoperative months, with no signs of recurrence, having good bone repair, and can be verified and proven through imaging tests, such as CFC, corroborating with the studies by Vasconcelos *et al.*<sup>14</sup> and Torres-Lagares *et al.*<sup>15</sup> on the gold standard of radiographic diagnosis.

However, to achieve good results during periapical cyst treatment, it is necessary to make a correct diagnosis, followed by adequate planning, always performing clinical and radiographic follow-up, in addition to the patient's cooperation, so that good results can be achieved during the treatment.

## 3 Conclusion

It was observed that a well-performed endodontic treatment, associated with a elaborated surgical technique, in addition to anatomopathological evidence and radiographic follow-up, make the therapeutic success to be obtained in cases of large periapical cysts.

## References

1. Amorim M, Damasceno E, Borges G, Souza D, Dias K. Remoção de combinações de cisto periapical na região anterior de maxila: relato de caso. *Pesq Soc Desenvol* 2021;10(15): . doi: <http://dx.doi.org/10.33448/rsd-v10i15.22905>.
2. Abdul Ghani N, Abdul Hamid N, Karobari M. Tunnel' Radicular Cyst and its management with root canal treatment and periapical surgery: a case report. *Clin Case Reports* 2020;8(8):1387-1391. doi: 10.1002/ccr3.2942.
3. Pereira JS, Milagres RM, Andrade BAB, Messoria MR, Kawata LT. Cisto Periapical de Grande extensão: relato de caso. *Rev*

- Cirur Traumatol Buco-maxilo Facial 2012;12(2):37-42.
4. Nanami R, Sampaio C, Olivete J, Pizzatto E, Moresca R, Giovanini AF. Prevalência de Cistos Maxilares Diagnosticados em um Centro de Referência Brasileiro. *Rev Sul-Bras Odontol* 2009;6(2):143-46. doi: <https://doi.org/10.21726/rsbo.v6i2.1207>
  5. Andrade Junior CV, Antunes HS, Carvalhal JCA, Dessaune Neto N, Uzeda M. Os Cistos Radiculares podem curar após tratamento endodôntico? *Rev Bras Odontol* 2014;71(1):99-102.
  6. Resende MAP, Assis NMSP, Dias ACS, Aguiar EG, Maior BSS. Tratamento cirúrgico e conservador de Cisto Periapical de Grande Proporção: relato de caso. *Rev UFJF* 2017.;43(2):191-6. doi: <https://doi.org/10.34019/1982-8047.2017.v43.2781>.
  7. Shah N. A Novel conservative approach combining “sealbio” and “surgical fenestration” for healing of large periapical cystic lesions of endodontic: a pilot study. *Contemp Clin Dent* 2017;8(3):367-2.
  8. Eloise CM, Rangel FGO, Barbosa CC, Barbosa OLC. Cisto Periapical tratado endodôntico e cirurgicamente: relato de caso. *Braz J Surg Clin Res* 2021;33(2):30-3.
  9. Oliveira LSS, Menezes ET, Salles LP. Tratamento endodôntico conservador de cisto periapical inflamatório: relato de caso. *Rev Odontol Planal Cent* 2018;10(1):19-22.
  10. Faria NSF, Monteiro VP, Barros AAP, Nicolau RA. Técnica de marsupialização e enucleação para o tratamento de cistos de grandes proporções: relato de caso. *Rev Bras Ciênc Saúde* 2012;16(3):467-74.
  11. Nobuhara WK, Del Rio CE. Incidence of periradicular pathoses in endodontic treatment failures. *J Endodontics* 1993;19(6):315-18. doi: [10.1016/s0099-2399\(06\)80464-4](https://doi.org/10.1016/s0099-2399(06)80464-4)
  12. Matsumura S, Murakami S, Kakimoto N, Furukawa S, Kishino M, Ishida T, et al. Histopathologic and radiographic findings of the simple bone cyst. *Oral Surgery Oral Med Oral Pathol Oral Radiol Endodontol* 1998; 85(5), 619-25. doi: [10.1016/s1079-2104\(98\)90301-8](https://doi.org/10.1016/s1079-2104(98)90301-8)
  13. Sjögren U, Hägglund B, Sundqvist G, Wing K, Sjögren U, Hägglund B, et al. Factors affecting the long-term results of endodontic treatment. *J Endodontics* 1990;16(10):498-504. doi: [10.1016/S0099-2399\(07\)80180-4](https://doi.org/10.1016/S0099-2399(07)80180-4)
  14. Vasconcelos RG, Queiroz LMG, Alves Júnior LC, Germano AR, Vasconcelo MG. Abordagem terapêutica em cisto radicular de grandes proporções: relato de caso. *Rev Bras Ciênc Saúde* 2012;16(3):467-74.
  15. Torres-Lagares D, Segura-Egea JJ, Rodríguez-Caballero A, Llamas-Carreras JM, Gutiérrez- Pérez JL. Treatment of a large maxillary cyst with marsupialization, decompression, surgical endodontic therapy and enucleation. *Canadian Dental Association* 2011;77:77-87.
  16. Bava FA, Umar D, Bahseer, B, Baroudi K. Bilateral Radicular cyst in mandible: an unusual case report. *J Int Oral Health* 2015;7(2):61-3.
  17. Schwartzman Cohen R, Goldberger T, Merzlak I, Tsesis I, Chaushu G, Avishal G, et al. The Development Of large radicular cysts in endodontically versus non-endodontically treated maxillary teeth. *Medicina* 2021;57(9):991. doi: <https://doi.org/10.3390/medicina57090991>.